

should be performed by the same physician whenever possible. Diagnostically relevant regions of the breast should be scanned and x-rayed in the same session and evaluated by the same eye. It is inefficient for a gynecologist to perform ultrasound while a radiologist takes the x-rays at a different time and location.

The **indications** for breast ultrasound are as follows:

- Investigation of palpable abnormalities
- Investigation of clinically occult mammographic findings (focal densities with smooth or ill-defined margins, circumscribed asymmetries)
- Radiographic breast density of ACR 2–4
- Previous silicone implantation, reconstruction, or augmentation
- Regular screening examinations in high-risk patients age 25 years or older, supported by mammography and magnetic resonance imaging
- Imaging guidance of diagnostic and therapeutic interventional procedures in the breast
- Questions relating to hormone replacement therapy in menopausal women

The physician who performs mammography—whether a radiologist or gynecologist—should have the option of performing both mammography and ultrasound and to order any necessary interventional procedures without delay.

Examination Technique

Generally the examiner should scan both breasts while applying carefully controlled transducer pressure. The examination should include both axillae, and the infraclavicular fossae should be scanned in follow-up examinations to rule out malignancy in the clavicular recess (see **Fig. 5.61**, p. 157 and **Fig. 5.54a**, p. 146), and the other recess (see **Fig. 4.24k**, p. 347).

The patient is usually positioned supine with the arms clasped behind the head. A semilateral or wedge-supported position may be helpful for evaluating the outer quadrants, especially in patients with large breasts.

With an oblique supine position, the breast is optimally flattened against the chest wall and even peripheral nodules will not slip out of the scanning plane beneath the transducer. The patient should not be examined in a standing or sitting posture unless she has noticed something peculiar in a certain position that is not reproducible in the supine position.

Contact pressure during the examination should be sufficient to provide clear differentiation of intramammary structures (fat, connective tissue, glandular parenchyma), but pressure should not be so high as to induce any pain. During scanning, the transducer should always be held perpendicular to the breast parenchyma as oblique scanning will cause artifacts.

The field of view should maximally occupy the width of the monitor screen. The pectoral fascia should form the lower (far) boundary of the scan and should be clearly defined. If the pectoral fascia cannot be clearly identified, the breast should be scanned at a lower frequency to allow deeper sound penetration.

Uniform focusing should be achieved between the skin and pectoral fascia, preferably through the use of multiple focal zones.

Scanning should be performed in overlapping planes to ensure complete coverage of the breast. Attention is given to the shape of

the breast parenchyma. It is best to use a radial scanning pattern, taking as a reference point the retroareolar region and the terminal duct lobular units of a particular mammary lobe. This is particularly important in the investigation of physiologic changes. The transducer is positioned radially for the analysis of individual lobes. From that position the transducer is angled and rotated to locate the principal duct of interest, which provides a landmark for anatomic orientation (**Fig. 5.60**). The breast is scanned primarily in horizontal and vertical planes, however, for the detection or exclusion of suspicious lesions.

The scan planes should be reproducible both in the documentation of abnormalities (scan plane centered over the tumor) and in the visualization of focal lesions. Reproducibility is aided by the body markers that are available in every system.

Tip

The documentation of an abnormal finding should at least cover a representative parenchymal region in each breast and should include the nipple region. The abnormality should be visualized and measured in two planes. The axillary region should also be documented if it has been scanned.

The **documentation of a focal lesion** should include the following data on lesion location:

- Affected side (right/left)
- Clock-face position of the lesion relative to the nipple
- Distance from the center of the nipple to the closest lesion margin (in mm or cm)
- Lesion depth = distance from the skin to the closest lesion margin (in mm or cm)
- Size of the lesion in three dimensions measured in two mutually perpendicular scan planes

The major tumor axis should also be indicated. In addition to purely metric data, the lesion should be characterized in terms of its echogenicity (e.g., a hypoechoic or hyperechoic core with an echogenic rim).

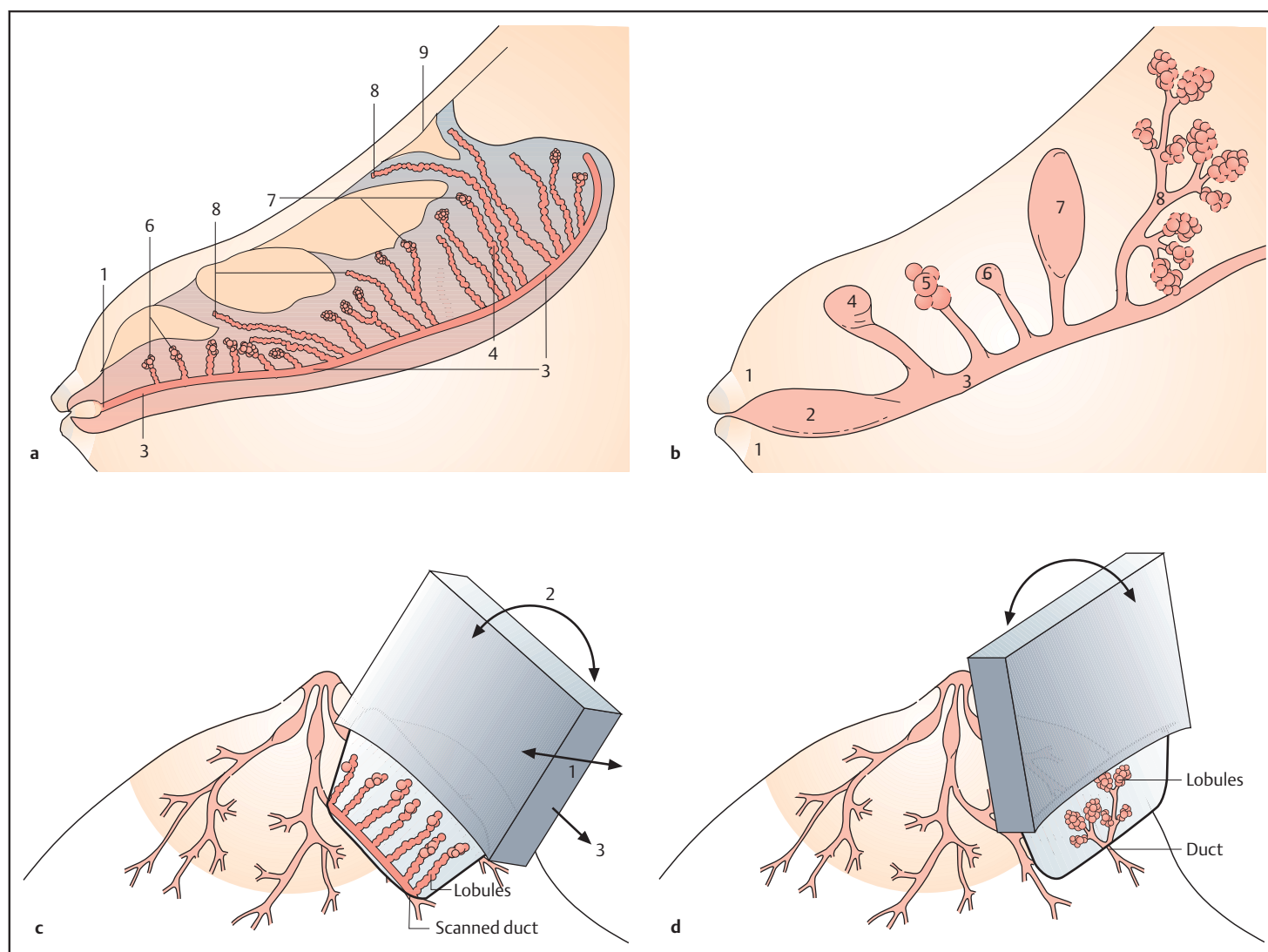
The following features are used to describe the **sonographic morphology** of a lesion:

- **Echogenicity** relative to surrounding tissues: anechoic, hypoechoic, isoechoic, or hyperechoic
- **Shape:** round, oval, complex, patchy
- **Margins:** smooth, lobulated, irregular, ill-defined
- **Internal echo pattern:** homogeneous, inhomogeneous, heterogeneous
- **Sound transmission:** shadowing, indifferent, enhancement
- **Surroundings:** satellite or second lesions, contralateral lesions
- **Axillary lymph nodes:** fatty, indifferent, suspicious, enlarged

The **breast ultrasound report** should include the following data and information:

- Patient identity
- Date of examination
- Essential information on the current and prior history (previous findings!)
- Indication for breast ultrasound
- Visual and palpable findings
- Sonographic findings
- Relationship to mammogram or magnetic resonance image (if available)

Fig. 5.60 Anatomy of the mammary lobes and scanning technique during breast ultrasound (from Teboul and Halliwell 1995).



a Diagrammatic representation of a mammary lobe in the retroareolar region (1). The lobules near the nipple (6) tend to be shorter and thicker than the peripheral lobules (4). Some lobules (7) run perpendicular to the main duct (3) (see also **Fig. 2.1a**) and overlap the anterior edge of the lobe, creating a cobblestone appearance (see **Fig. 5.70 d**). Others (8) extend into the Cooper ligaments and pass with them into the cutaneous fascia (9).

b Anatomy of the terminal duct lobular unit: nipple and retroareolar region (1), lactiferous sinus (2), lactiferous duct (3), and the most common types of lobule (4–7): short, thick lobule close to the nipple (4), lobule with microcystic degeneration (5), atrophic lobule (6), cystic enlargement of a lobule (7), and multiple lobules with branched connections (8). Lobules usually exhibit a cloverleaf shape in the periphery.

The *terminal duct lobular unit* of Wellings (1972) is a complex formed by the ductolobular and tubular units and containing acini and terminal ducts. The terminal duct lobular units (TDLUs) are the basic milk-producing units of the breast.

Most carcinomas originate in the TDLU and are basically ductolobular carcinomas (see also **Figs. 4.12, 4.13**, p. 31). During *maturation* of the breast, the lobules sprout from the surface of the main ducts and extend toward the skin, emphasizing the importance of maintaining firm transducer contact during ultrasound scanning.

c Axial (radial) scan along a milk duct. Scanning in this plane most clearly defines the lobules in relation to their surroundings. Ideally, each individual lobe should be analyzed separately, but in practice this is necessary only if an atypical lesion is found.

The most important sonographic criterion for lobular stimulation is lobar prominence. Radial scanning of the lobes (1) provides the best overview of ductolobular structures and most clearly depicts their pathology and physiology. Some lobules may extend a distance from the main duct and project into the skin or angle back toward the duct.

Transducer position should be tailored to individual anatomy. The probe can be angled from its radial placement along the duct (2) to compensate for the variable position of the TDLUs. Normally the ducts can be traced to the periphery of the lobe by radial advancement of the probe.

d Transverse scans are directed at right angles to the main duct, providing cross-sectional views of the duct and afferent ductules. The lobules that connect with the terminal duct may occasionally form a stellate arrangement. Sometimes these anatomic patterns are definable, but only with a 13–18 MHz probe.

The ultrasound report should consist of several parts:

- A description of the parenchymal structure to determine assessability
- Localization
- Biometry and sonographic morphology of focal lesions
- Associated findings

Finally, a BIRADS score is determined to express the overall **level of suspicion** for a given lesion (ACR BIRADS):

- **Category S1:** negative
- **Category S2:** benign finding (e.g., cyst)
- **Category S3:** probably benign (follow-up in 6 months)
- **Category S4:** suspicious abnormality (4A, low; 4B intermediate; 4C moderate suspicious)
- **Category S5:** highly suspicious of malignancy
- **Category S6:** histologically confirmed malignancy

Each category is associated with a **recommended action** that includes follow-up intervals and the possible need for further diagnostic or interventional measures.

Schematic Protocol of Ultrasound Examination

The traditional analysis of malignant structures in breast ultrasound is based almost entirely on the geometry of the lesion while ignoring basic anatomic structures—the ductal and lobular parenchyma.

Teboul and Halliwell (1995) defined benign and malignant criteria for the *terminal duct lobular unit (TDLU)* that are not widely known or utilized. In this approach it is not enough to scan the breast in horizontal and vertical planes to look for atypical lesions; it must also be scanned radially along the course of the duct and documented (**Fig. 5.61 c**), especially for the investigation of tumors or changes during the course of the menstrual cycle. Follow-up examinations should be interpreted with reference to this baseline documentation so that the same segments can be comparatively analyzed. This is the only way to evaluate changes in the TDLUs over time, and it facilitates the detection of new lesions. It also ensures an overlapping examination of all breast segments, which is of forensic importance (**Fig. 5.61 c**).

This examination, then, includes evaluation of the lactiferous ducts, mammary lobes, and lobules. There are many cases in which this analysis can give form and meaning to apparent architectural disarray in a breast sonogram. To make a sonographic analysis of this kind, examiners must have a thorough knowledge of the pathoanatomy of the breast so that they can localize changes to specific anatomic structures (ducts, connective tissue, Cooper ligaments, skin, muscular fascia, pectoral muscles). The diagnosis should be a descriptive one that is stated in relation to these anatomic structures (see p. 23 ff).

Increasingly, breast ultrasound should come to rely more on morphology as a basis for diagnostic analysis. The geometry and margins of a lesion must be placed within an anatomic context.

Teboul and Halliwell (1995) draw the following conclusions:

- A meticulous, duct-oriented sonographic analysis of the breast parenchyma is essential for planning cancer treatment and detecting abnormal parenchymal responses to hormonal stimuli, for example.

- The key to this analysis lies in identifying the terminal duct lobular units (TDLUs) within the breast and determining their relationship to pathologic changes.
- Duct-oriented ultrasound is the only sure way to establish anatomic orientation in the breast and define the relationship between the breast parenchyma and the structures around it.

This kind of localization and identification can often, though not always, be accomplished with a high-resolution transducer (11–18 MHz). Structural analysis of the lobules and TDLUs in response to hormone replacement therapy or contraceptive use, for example, has the potential to become an important and previously unutilized approach in modern diagnostic ultrasound.

It would be desirable for manufacturers to produce higher-frequency transducers as well as ultrasound systems in which the last examination could be automatically displayed on a separate screen for reference, similarly to **Fig. 5.61 d**. The examiner should always work in the same direction, beginning in the axilla and ending at a 6 o'clock position with each breast (see **Fig. 5.61 c**). He/she can thus be sure that each breast quadrant is examined twice and that comparable documents are available for future examinations. The examiner should always follow the same systematic sequence when performing breast ultrasound in order to obtain comparable results (see **Fig. 5.61 d**).

Basic Structures of the Breast and their Variants on Ultrasound, with Mammographic Correlation

The basic structures of the breast can be analyzed reasonably well with high-resolution transducers. Fat and glandular tissue show contrasting echogenicities. Fatty tissue is dark (hypoechoic), while the glandular tissue, consisting of lobular parenchyma and the intra- and interlobular stroma, appears bright (hyperechoic) (see **Fig. 5.75 e, f**, p. 177). Within the breast parenchyma, the lobes are difficult to distinguish from one another, although this can be done indirectly by visualizing the major ducts. The lobules and TDLUs appear as small, dark (hypoechoic) round to oval structures that are clearly distinguishable from the hyperechoic fibrous septa (see **Fig. 5.65**, p. 163). This requires that the TDLUs are in a proliferative state and are not atrophic (see Chapter 4, p. 23).

The breast consists of up to 12 lobes, each based on a major duct that runs a straight or tortuous course (especially in the retroareolar region) from the nipple to the periphery of the breast. Only radial scanning can define all or part of the main duct, which appears as a hypoechoic channel. The TDLUs (lobules with acini and functional intralobular stroma) are found in proximity to the ducts. The TDLUs are not very well developed before 18 years of age. If they are detectable at all, they appear as focal hypoechoic areas during the second half of the menstrual cycle or the premenstrual phase. Fat and connective tissue (interlobular fibrosis) predominate normally in the adolescent breast (see **Figs. 5.63**, p. 160). Exceptions are possible especially some weeks before menarche (see **Fig. 5.62 a–d**, p. 159) and in cases of malignancy (see **Fig. 5.64**, p. 161).

More lobule-bearing areas can be found in the postpubescent breast. Lobules may be seen in various areas up until the first pregnancy, usually in the relatively long lateral superior lobes in the upper outer quadrants. The lobules become larger and more dense shortly before and during menstruation. Afterward they regress until ovulation, then enlarge again during the second half of the cycle

until the next period (see **Figs. 5.65–5.67**, p. 163 ff). The TDLUs are very prominent and easily visualized (often right after ovulation) in women with severe premenstrual complaints, although premenstrual syndrome may occur in the absence of lobular proliferation. The reason for this is unknown.

The lobules are most abundant during pregnancy and lactation, when the breast consists predominantly of milk-producing glandular parenchyma while fat and connective tissue are displaced to the margins of the greatly enlarged TDLUs. The main ducts are dilated, and their fluctuating milk contents can be clearly visualized (see **Figs. 5.68–5.70**, p. 168 ff).

After lactation is completed, focal enlargement of the lobules persists for a period of several months to years (see **Fig. 5.69**, p. 170). After that time the lobules gradually regress to a normal state. Maturation of the breast is complete following the first pregnancy (see p. 7).

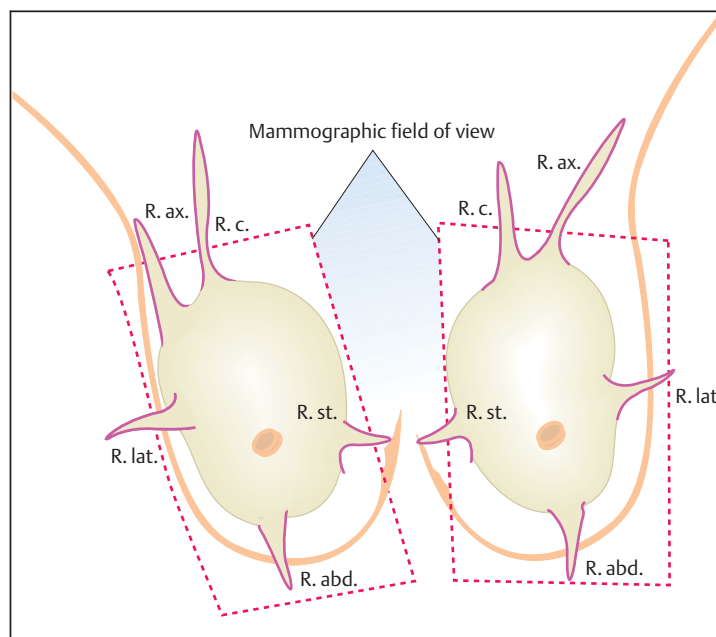
Starting at about age 40 years and after menopause, the TDLUs continuously regress from the periphery of the breast toward the nipple, again resulting in a predominance of fat and connective tissue. For unknown reasons, some women retain a substantial volume of lobular tissue after age 40. As a result, approximately 30% of menopausal women have relatively dense mammograms, also due in part to an increase in connective tissue (see p. 98). Researchers should investigate whether these breasts are responding to endogenous or exogenous hormonal stimulation and whether this may in-

crease the risk of breast cancer (especially lobular neoplasms). The *changing* radiodensity of the mammogram depends on the proliferation of TDLUs and not on the interlobular stroma (see p. 23). In any case it could be extremely useful for gynecologists to detect cyclic and atypical lobular proliferation in the breast in order to evaluate hormonal responses. Menopausal women with proliferating TDLUs who are on hormone replacement therapy could be prescribed a different hormone (e.g., an estrogen-only product, especially after hysterectomy) or might discontinue HRT if a different hormone is found to have no effect on lobular regression. Women who do not show significant lobular proliferation at ultrasound presumably would not have an increased breast cancer risk with HRT. Women who do show TDLU proliferation in response to tamoxifen, for example, should be tested for paradoxical hyperestrogenemia, which may require the discontinuation of tamoxifen.

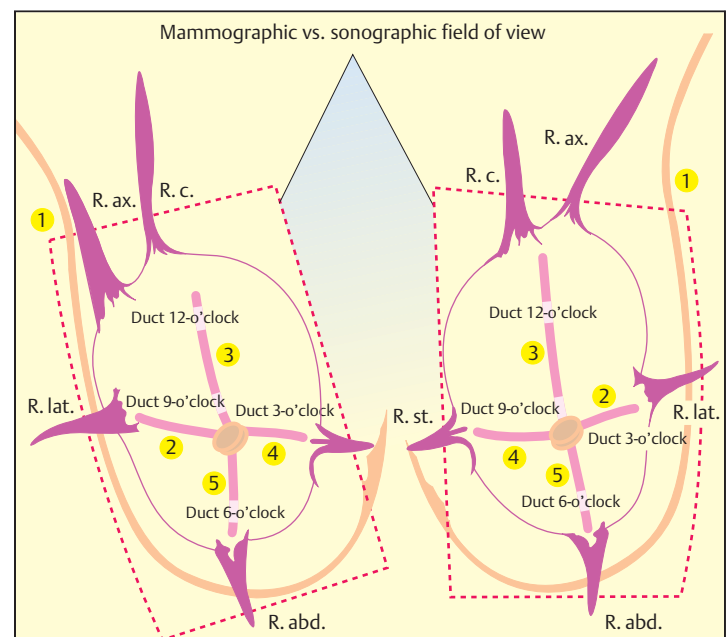
These and other facts have not yet been scientifically investigated but could become important in gynecologic consultations. Ultrasound has yet to fulfill its potential. There are still unsuspected possibilities in the assessment of patients on HRT, perhaps including the use of higher-resolution transducers or even probes that could be “tuned” to the hormone status of individual patients.

Figs. 5.71–5.83 (p. 172 ff) illustrate numerous cases with mammography and ultrasound imaging which may be diagnostically misleading but which can be considered to be within the realm of normal, non-malignant variants.

Fig. 5.61 Protocol for breast ultrasound. The examiner should always follow the same routine when performing breast ultrasound in order to obtain comparable results. In particular, the scans should cover breast regions that are not depicted in mammograms—most notably the recesses (axillary, clavicular, sternal, abdominal, and lateral) (**a**). Sonographic coverage considerably therefore exceeds mammographic coverage (**b**). Starting from the right axilla, the scans should proceed to the lateral, upper, medial, and lower quadrants in an overlapping pattern, and the ducts associated with each quadrant should be documented at approximately the 9-, 12-, 3-, and 6-o'clock positions. The same procedure is followed in the left breast, providing mirror-image information on the breast parenchyma and ensuring that all quadrants are examined twice. This consistent routine has forensic importance as well (**c**). Previous sonograms should be available for follow-ups to facilitate the prompt detection of pathologic changes and physiologic variations in the glandular tissue (**d**). This is effectively accomplished in the digital age by using worklists supplied by equipment manufacturers.



a Diagram of the recesses and the area covered by mammography (brown shading). Mammograms cannot fully cover the axillary recess (R. ax.), clavicular recess (R. c.), sternal recess (R. st.), abdominal recess (R. abd.), or lateral recess (R. lat.). Some changes, especially in the sternal recess, are not mammographically detectable in obese women (see **Fig. 4.24e**, p. 50, **Fig. 4.24j, k**, p. 347).



b Ultrasound coverage of the breast parenchyma. The yellow-shaded area represents the area accessible to ultrasound scanning. The ducts (2, 3, 4, 5) and axilla (1) are indicated in red. These duct-oriented scan planes through the breast parenchyma permit an accurate assessment of physiologic responses to hormonal stimuli, etc.