

## Skin Structure and Biology

Wei-Meng Woo

Nanyang Technological University, Lee Kong Chian School of Medicine, Clinical Sciences Building, 11 Mandalay Road, Singapore, 308232, Singapore

### 1.1 Introduction

The integument system of an animal serves as a boundary to protect the interior organs from external assaults, prevents the loss of heat and water, and maintains osmotic pressure. The simplest form of integument is exemplified by the diploblastic (two germ layers: ectoderm and endoderm) body plan of cnidarians, such as hydra, whose single-cell layered ectoderm (integument) supports and protects its endoderm (guts: internal organ). In vertebrates, the integument include skin and specialized structures derived from the skin. These skin-derived specialized structures range from scales in reptiles, feathers in birds, to furs/hairs in mammals. Hairs, nails, claws, sweat glands, and teeth are skin derivatives and are also part of the integument of vertebrates [1, 2]. Analogous to the diploblastic animals, in these triploblastic (three germ layers) animals, their ectoderm (epidermis) and mesoderm (dermis) protect their endoderms (internal organs).

In human, skin constitutes 15–20% of the body mass, as such, it is the largest organ of the human body. As the outermost layer, the human skin acts as an interface between our body and the environment; it protects the underlying tissues and internal organs and also responds to external stimuli, avoiding dangers and injuries.

As a physical barrier, skin provides the first line of defense against environmental hazards. Skin protects our body from UV damage, chemical and mechanical assaults, injuries, and invasion of microorganisms. From the interior, skin protects our body from water loss, preventing dehydration, which could be life-threatening. Furthermore, skin contributes to body temperature regulation, which is achieved by sweating and insulation. Through sweating and a water barrier function, the skin helps maintain the balance of water and electrolytes. The skin is also a sensory organ; with its touch, thermal, and pain sensors, it informs the brain of changes in the immediate environment. In addition to a physical barrier, the skin's protection against microbes also come from the its immune response and production of pathogen fighting peptides [3]. On a different note, perhaps part of a protection function (for the bone), vitamin D is synthesized in the skin.

In this chapter, the structure and organization of the human skin and its cellular composition and functions, with additional focus on the formation of the stratified epidermis and of a water barrier, will be introduced.

## 1.2 Skin Structure

### 1.2.1 Overview of Skin Tissue Organization

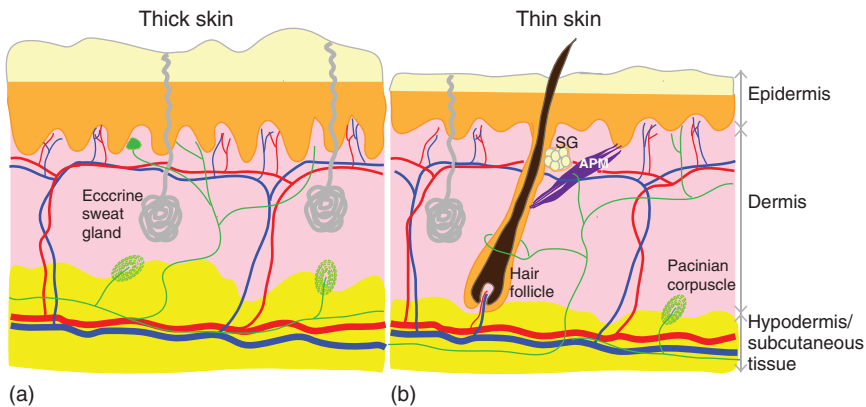
The skin organ consists of three tissue layers: from the surface to the interior are the epidermis, dermis, and hypodermis. The organization of these three tissue layers is also reflected in their names: the “epi-”dermis sits on top of the dermis, and the “hypo-”dermis sits below the dermis. Historically, and still a well-recognized definition, the epidermis and dermis form the cutaneous tissue (Latin - *cutis*: the skin). Under this definition, the skin is composed of only epidermis and dermis, whereas the hypodermis is the subcutaneous tissue, which is not part of the skin. The cutaneous tissue rests on the hypodermis, which connects and anchors the cutaneous tissue to the underlying fascia [4, 5].

In mammals, the epidermis is a form of stratified squamous epithelium, which means it is layered (stratified) and scale-like (squamous). This is in contrast to the simple epithelium that is single layer, which can be found as lining of internal organs such as lungs and livers. The epidermis consists mostly of epithelial cells that are commonly known as keratinocytes, which are protein-rich epithelial cells with abundant keratins and keratohyalin. Keratinocytes in the outermost epidermal layer are flatten and enucleated, forming a scale-like or cornified pattern that is water impermeable, thereby contributing the most prominent function for the skin: water barrier. The dermis is a connective tissue with fibroblast cells interspersed in a collagen – elastin-based extracellular matrix. Blood vessels, lymphatic vessels [6], nerve endings [7], and appendages including hair follicles, sebaceous glands, and sweat glands reside in the dermis. The hypodermis is composed of adipose tissue, which serves as energy storage and insulation for the body and serves as a cushion for the skin. It is also the origin of some blood vessels that extend to the dermis.

The epidermis and dermis are physically separated by a basement membrane. By contrast, dermis and hypodermis are not physically separated. The basement membrane consists of extracellular matrix components that the epidermis attaches to; this kind of attachment mechanically supports the epidermis. The epidermal–dermal junction undulates with finger-like projections of the dermis into the epidermis, forming a dermal pattern termed the dermal papilla. Fingerprints are the results of the ridges that formed by dermal papillae under our fingertips. In addition to providing mechanical support for the epidermis, dermis also supports the epidermis with nutrients via its blood vessels in the dermal papillae.

#### 1.2.1.1 Thick Skin and Thin Skin

The human skin can be categorized as thick skin and thin skin, based on skin compositions, epidermal thickness, and epithelial layers, although the most earliest notable difference is the epidermal thickness. Thick skin is found in areas



**Figure 1.1** (a) Thick skin and (b) thin skin (hairy skin). Thick skins are found in the palms, soles, and at the surface of fingertips and toes. Thin skins cover most part of the body, and they contain hair follicles thus also known as hairy skins. While thick skin has thicker epidermis, their dermis is thinner, and they lack hair follicles, sebaceous glands and arrector pili muscle. In thick skin, there are more sensory receptors such as Meissner's and Pacinian corpuscles. APM: arrector pili muscle, SG: sebaceous gland. Red: arteriole, blue: venules, green: nerve fibers, Meissner's corpuscle (near epidermis).

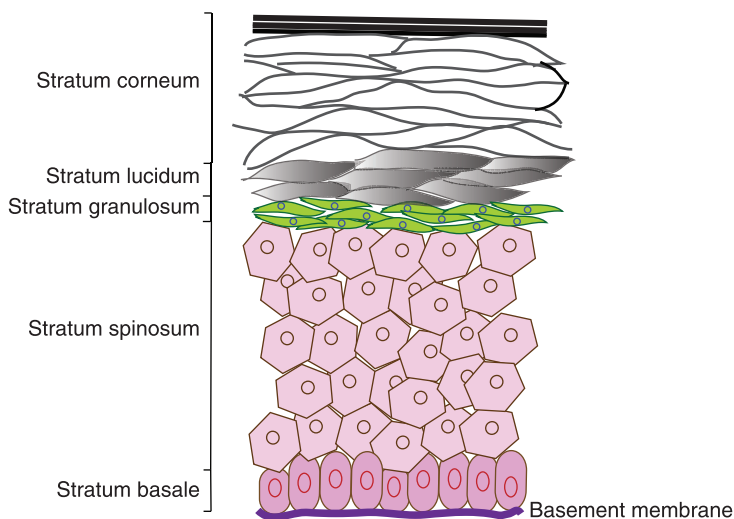
where abrasion occurs frequently, including the palms, soles, fingers, and toes. Thin skin covers a large proportion of the body, most of the thin skin have hairs, so thin skin is also known as hairy skin. By contrast, thick skin is hairless – they do not have hair follicles nor do they have sebaceous glands. However, thick skin has more sweat glands and sensory receptors than thin skin.

As their names imply, thick skin is thicker than thin skin (Figure 1.1). The thickness of thin skin is around 1–2 mm, whereas thick skin can reach a thickness of 6 mm. This is prominent at the epidermis level where the thick skin epidermis is considerably thicker than thin skin epidermis. The individual epithelial layers of the thick skin are thicker than those layers in the thin skin, especially the outermost layer, the stratum corneum, which can become remarkably thick. Another distinct feature of thick skin is that they have five epithelial layers with a distinct stratum lucidum below the stratum corneum, while in thin skin there are four epithelial layers (Figure 1.1 and Section 1.2.2). Underneath the epidermis, dermal papillae in thick skin are more regular and deeper than those in thin skin, although dermis of thick skin is relatively thinner.

The thickness of human skin varies at different body locations [8–12]. The thickness of human epidermis ranges from 0.05 to 1 mm, whereas the dermis is about 1–2 mm thick. The thinnest skin is found on the eyelids: the epidermis of eyelids is 0.04 mm, the dermis of eyelids is 0.3 mm. In contrast, the epidermis of the palms and soles is 1.6 mm, whereas the dermis on the back reaches 3 mm.

### 1.2.2 Epidermis

As mentioned in the overview (Section 1.2.1 and subsection 1.2.1.1), the human epidermis is a stratified squamous epithelium and is categorized as thin and thick



**Figure 1.2** Schematic diagram of five epithelial layers in the epidermis of thick skin. The stratum lucidum is absent in thin skin. The epidermis is connected to the dermis via the basement membrane.

skins. The epidermis in thin skins consists of four layers of epithelial cells, while in thick skins there are five layers of epithelial cells (Figure 1.2). In thin skin, from the bottom to the top, or from deep to superficial, the epidermal layers are the stratum basale (basal cell layer), stratum spinosum (spinous layer or suprabasal layer), stratum granulosum (granular cell layer), and stratum corneum (cornified layer). In thick skin, an additional layer, the stratum lucidum, is present between strata granulosum and corneum. These five layers are further introduced in Subsections 1.2.2.1–1.2.2.5.

The stratified epidermis consists predominantly of epithelial cells known as keratinocytes, which express a substantial amount of keratin proteins that form keratin filaments and keratohyalin. At the epidermal layer level, keratinocytes of each epidermal layer are characterized by the expression of a specific pair of keratin proteins, usually a basic and an acidic keratin protein. For example, keratinocytes of the stratum basale produce keratin 5 (K5, belongs to basic keratins) and K14 (acidic keratins) proteins, whereas keratinocytes in stratum spinosum produce K1 (basic keratins) and K10 (acidic keratins). The specific pair of keratin proteins forms obligate heterodimers and constitutes the fundamental subunit of the keratin intermediate filament. The keratin intermediate filaments stretch across the cytoplasm of the keratinocytes, giving the epidermis its tensile strength, shape, and resilience to mechanical insult.

Whereas keratinocytes make up over 90% of the epidermis, there are a small percentage of non-epithelial cells reside in the epidermis. These cells include melanocytes, Langerhans cells, and Merkel cells. While the keratinocyte is responsible for the mechanical and water barrier function of the epidermis, melanocytes, Langerhans cells, and Merkel cells are responsible for skin pigmentation, immune protection, and sensory (touch) functions, respectively.

### 1.2.2.1 Stratum Basale

The stratum basale (basal layer) is made up of a single layer of basal epidermal cells. These cells are also known as basal cells or basal keratinocytes. Basal keratinocytes are cuboidal in shape with relatively big nucleus. Within a basal keratinocyte, K5/K14 intermediate filaments run perpendicular to the skin surface, and they attach to the hemidesmosomes on the basal surface of the cell, thereby anchoring basal keratinocytes to the basement membrane. Epidermal stem cells interspersed in this layer; during normal homeostasis, these are the resident epidermal stem cells that generate all the keratinocytes in the epidermis.

In addition to keratinocytes, two types of non-epithelial cells, melanocytes and Merkel cells, immigrate and reside in the stratum basale. Melanocytes originate from the neural crest, and they produce melanin that contribute to skin pigmentation. In the stratum basale, melanocytes constitute about 3% of the cell population. Although they reside in the stratum basale, melanocytes are not connected with basal keratinocytes. Instead, their long dendrites extend to the stratum spinosum, making connections with keratinocytes in the stratum spinosum. In melanocytes, melanin are generated and packed in melanosomes, which are then transported via extended dendrites from the melanocyte cell body to the keratinocytes in the stratum spinosum. These melanosomes surround the nucleus of the keratinocytes, shielding them from UV rays. Sun exposure and genetics determines the amount of melanin produced, but everyone has about the same numbers of melanocytes. Of note, there is another group of melanocytes that immigrate to and reside in the hair follicles. The hair follicle resident melanocytes contribute to hair pigmentation but not to skin/epidermal pigmentation. Merkel cells are thought to function as touch receptors. In line with its function, Merkel cells are more abundant at the fingertips. However, the origin of Merkel cells is not clear.

### 1.2.2.2 Stratum Spinosum

The stratum spinosum (spiny layer) acquires its name from its spiny appearance in stained specimens, it is also known as the suprabasal layer. Stratum spinosum consists of eight to ten sublayers of polygonal-shaped keratinocytes. The spiny appearance of the stratum spinosum comes from protrusion structures generated by desmosomes that interconnect their keratinocytes. Suprabasal/spinous keratinocytes can be differentiated from the basal keratinocyte by the specific expression of K1 and K10 intermediate filament proteins. The K1/K10 dimers form intermediate filaments that extend radially, spanning the cytoplasm and inserting into the desmosomes at the cell periphery. The spinous keratinocytes produce water-repelling glycolipids. Overall, the spinous layer contributes to skin strength and flexibility.

In addition to keratinocytes, Langerhans cells are also found in the stratum spinosum. Langerhans cells are dendritic cells with flatten dendrites that extend along a horizontal plane in the epidermis. The cell body and extended dendrites of Langerhans cells generate a 25% coverage of the skin surface. With such coverage, Langerhans cells are efficient at recognizing and capturing antigens and other foreign substances in the epidermis.

#### 1.2.2.3 Stratum Granulosum

As its name indicates, stratum granulosum appears grainy. With three to five sublayers, their keratinocytes are flatter in cell shape, with thickened cell membrane. Keratinization begins in this layer; the grainy appearance is generated by keratins and keratohyalin (lamellar granules) in the keratinocytes. These keratohyalin granules are made up of profilaggrin, which is a ~400–500 kDa protein that will be cleaved into ~26–48 kDa filaggrins (*filament aggregating proteins*). The cleavage of profilaggrin occurs as the keratinocytes move from the stratum granulosum to stratum corneum. Enucleation happens as granular cells differentiate to corneocytes, specialized keratinocytes of the stratum corneum (sub-section 1.2.2.5). Tight junctions are formed in the granular cells, which also contribute to a barrier function.

#### 1.2.2.4 Stratum Lucidum

This layer is only present in the epidermis of thick skin, mainly at the palms and soles. Microscopically, the stratum lucidum has a smooth and seemingly translucent appearance, hence its name. Their keratinocytes are further flattened and are dead cells. The lucidum keratinocytes are densely packed with eleiden, a lipid-rich protein that is derived from keratohyalin and contributes to water barrier function.

#### 1.2.2.5 Stratum Corneum

The stratum corneum, or the cornified layer, is the main layer that contributes water barrier function for the skin. Stratum corneum is about 10–20  $\mu\text{m}$  thick and consists of 15–20 sublayers of flattened keratinocytes with their nuclei removed (enucleated or anucleated). Keratinocytes in this layer are terminally differentiated and nonviable, and they are also known as corneocytes. Corneocytes are filled with keratin filaments; underneath corneocytes' plasma membrane, keratins, filaggrin, loricrin, involucrin, and a few other proteins assemble into a cornified envelope of ~10–15 nm thick. These proteins are cross-linked by transglutaminases. This cornified envelope becomes the structure to which both intracellular keratins and intercellular lipids attach to.

While the outermost layer of stratum corneum is desquamated, or sloughed off, continuously, the proliferation rate of epidermal stem cells in the stratum basale matches the desquamation rate such that a water barrier is always present.

### 1.2.3 Dermis

Dermis provides support and nutrients for the epidermis. The dermis is essentially a connective tissue with cells comprising only 10% of its content, while acellular components comprise the majority of its content. The major cell type in the dermis is the fibroblast, spindle-shaped cells that are mainly originated from the mesoderm and express the intermediate filament vimentin. Dermal fibroblasts deposit collagens and elastins to their extracellular space, forming meshwork of collagen and elastin fibers in a gel-like ground substance. Collagen fibers make up 70% of the dry weight of dermis, whereas elastin fibers make up less than 1%. Collagen fibers confer high tensile strength, whereas elastin fibers confer the ability of skin to return to its original shape upon deformation by external forces. Ground substance is also produced by fibroblasts, and it makes up about

0.2% of the dry weight of dermis but constitutes most of the dermal volume. The main composition of ground substance is glycosaminoglycans; together with its other compositions including water, electrolytes and plasma proteins, ground substance plays important role in salt-water balance and provides support for other components in the dermis.

Within the dermis, two “layers” of dermis can be readily observed: the upper layer is the papillary dermis, and the lower layer the reticular dermis, without distinct boundaries. The extracellular matrix meshwork that each layer produces are interconnected. The papillary layer is a loose connective tissue with relatively more fibroblast cells, and their collagen fibrils and elastin fibers are thinner and loosely organized. As described in the overview section of this chapter, the papillary dermis extends to the stratum basale of the epidermis forming finger-like dermal papillae. By contrast, the reticular layer is a dense connective tissue. Relatively fewer fibroblast cells are present in the reticular dermis, along with less ground substance. The reticular pattern of this layer is due to a tight meshwork of collagen and elastin fibers, with thick collagen bundles arranged more or less parallel to the skin. Elastin fibers in the reticular dermis are coarse and form irregularly organized arrays. In addition to differential organization patterns of collagen and elastin fibers, dermal fibroblasts in the papillary and reticular dermis produce distinct sets of proteins and respond differently to stimuli and injuries [13, 14].

Whereas fibroblasts comprise the major cell type in the dermis, a number of non-fibroblast cells are present in the dermis. These non-fibroblast cells include adipocytes, macrophages, mast cells, and other circulating immune cells. In addition to these resident and immigrant cell types, the papillary dermis is supplied with abundant blood capillaries, it also consists nerve fibers, touch receptors known as Meissner corpuscles, and lymphatic vessels. Reticular dermis is also well vascularized, with sensory and sympathetic nerves located in this dermal layer. The blood vessels in the dermis form extensive networks or plexuses that extend to underneath the stratum basale (Figure 1.1). These blood vessel networks supply the skin with nutrients; importantly, for external substances applied topically or injected into the skin, such blood vessel networks provide them an access to the systemic circulation. Overall, dermis confers elasticity, pliability, and tensile strength to the skin, and it also supports the skin with nutrients, water–salt balance, touch and sensory reception, and defense against foreign agents.

#### 1.2.4 Hypodermis

The hypodermis connects the epidermis and dermis to the underlying fascia. The hypodermis is primarily adipose tissue and is well vascularized; it is the origin of some blood vessels that extend to the dermis. Similar to blood vessels in the dermis, blood supply in the hypodermis acts to supply the skin with nutrients while also acts as the entry to systemic circulation. Mechanosensory receptors in the hypodermis, known as Pacinian corpuscle, are localized near the dermis. Pacinian corpuscle is composed of Schwann cells that are concentrically arranged, with a central afferent nerve (Figure 1.1). Overall, the hypodermis is a loose connective tissue that provides cushioning and blood supply for the dermis and epidermis.



### 1.2.5 Skin Appendages

The major skin appendages are found in the dermis. These appendages include hair follicles, sebaceous glands, eccrine glands (sweat glands), and apocrine glands. Hairs offer warmth; sebaceous glands secrete sebum to lubricate hairs and epidermis; and eccrine glands excrete sweat (water), thus regulate body temperature as water evaporation generates a cooling effect on the skin. These appendages are generated by epithelial downgrowths that extend to the dermis. With openings to the outer environment, appendages especially hair follicles, become a passageway for external substance to enter the skin.

Hair follicle, or hair root, is the portion of the hair follicle appendage that locates under the skin surface, whereas hairs are the skin exposed portion of hair follicle shafts. A hair follicle is composed of seven concentrically organized tubular layers of differentiated epithelial cells, with a group of dermal fibroblasts aggregates at the base of this hair follicle epithelium. This dermal component is also named the dermal papilla (not to be confused with the finger-like dermal papillae of the papillary dermis). The outermost tubular layer of hair follicle epithelium is the outer root sheath, which is a continuous layer with the basal epidermal layer. Interior to the outer root sheath is the inner root sheath, further inside is the hair shaft proper. The lowest portion of hair follicle epithelium is the hair bulb, which consists of actively proliferating hair epithelial progenitors. As hair follicle matures, hair shaft extends beyond the skin surface through a channel formed by the differentiated hair follicle epithelium. Although not as noticeable as the scalp hairs, most other parts of the human body are covered with hairs, exceptions being the lips, palms, soles, and back of ears. These are the vellus hairs, which are shorter, thinner, and lighter-pigmented than that of scalp hairs.

Sebaceous gland is located at the upper portion of hair follicle.; together, the two are named the pilosebaceous units. Sebaceous gland is composed of polyhedral cells with small nuclei and pale cytoplasm that filled with lipids. It has lobule that opens into the hair follicle and secretes sebum, forming oily coating for the hair and skin. In addition to sebaceous glands, hair follicles are associated with blood vessels and nerve endings, receiving inputs from the vessels and nerves. A muscle tissue, the arrector pili muscle, attaches to the hair follicle at a position below the sebaceous gland, connecting hair follicle sheath to the dermis. Contraction of the arrector pili muscle moves hair follicle to a more upright position, generating goose bumps appearance.

The eccrine gland, or eccrine sweat gland, is a single long tube that is straight at the upper region but highly coiled at the lower part in the deep dermis. Eccrine gland is composed of one layer of cuboidal cells surrounded by myoepithelial cells. Salt and water are produced by the gland but the duct will absorb salt, thereby, sweat secreted is hypotonic. Eccrine gland has its independent opening to the skin surface. Sweat evaporation after its secretion helps cool the body. Eccrine glands are broadly distributed, except a few areas like lips and foreskin, whereas they are more abundant in palms, soles, and axillae.

Apocrine gland is distributed in the axilla, areola, and nipples. Although it is referred to as sweat gland, apocrine gland is more of a scent gland. Apocrine gland is originated from hair buds, and it has a single duct that opens to



the upper hair follicles. Their acini or secretory portion is in the subcutaneous layer (hypodermis) and are larger than those of eccrine glands. Apocrine glands undergo cell decapitation for secreting their products, which are viscous, milky, and odorless. The secretion will be smelly when they are broken down by bacteria and produce short-chained fatty acids, which generates body odor.

## 1.3 Skin Biology

### 1.3.1 Homeostasis: Epidermal Self-renewal

A critical function of the skin is to prevent water loss; otherwise, desiccation and death may ensue. Based on the organization and properties of the stratified epidermis, it is generally recognized that the primary role of the stratified epidermis is to generate a water barrier [15]. This is mainly achieved by the formation and maintenance of the stratum corneum. Through a periodical self-renewal of the epidermis, as old corneocytes sloughed off from the stratum corneum, a continuously supplied new corneocytes replace the loss, thus maintaining a water barrier.

This epidermal self-renewal occurs during normal homeostasis of the stratified epidermis upon activation of the resident epidermal tissue stem cells, which are distributed in the stratum basale [16, 17]. Once activated, the resident stem cell undergoes cell division such that two daughter cells are generated in the stratum basale. In most cases, of the two daughter cells generated, one of them will remain as an epidermal stem cell and stays in the stratum basale, whereas the other daughter cell will be destined for differentiation and will move upward to the suprabasal layer. It is believed that such upward movement is driven by a push from the newly added basal cell, which is the differentiating daughter cell generated from stem cell division. Similarly, the epidermal cells in the suprabasal layer further differentiate and move upward to the granular cell layer, in which the existing granular cells undergo maturation and enucleation as they move upward to the stratum corneum. It takes about 14 days for a keratinocyte to transit from the stratum basale to the stratum corneum and another 14 days for keratinocytes within the stratum corneum to turnover. Therefore, the turnover and renewal of the epidermal layers are well balanced. These processes are part of the normal homeostasis of the skin. Having said that, age and inflammatory conditions can adversely affect these processes.

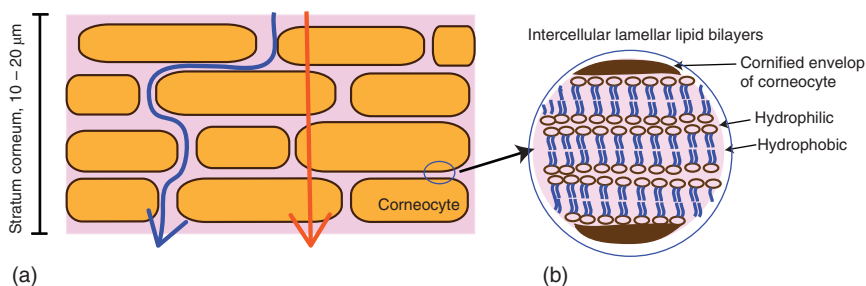
Beyond normal homeostasis, the stratified epidermis will be regenerated if it is lost due to injury or wounding [17]. In this case, studies in mouse skin revealed that epithelial stem cells from the hair follicles will also be activated and participate in re-epithelializing the wound [18]. The re-epithelialization forms the first one or two layers of the epidermis, which prevents infection and further injury. Nevertheless, the contribution of most hair follicle stem cells is transient, whereas epidermal stem cells from the stratum basale of the nearby uninjured skin region are responsible for reforming a stratified epidermis that can undergo long-term self-renewal. The subsequent epidermal stratification is necessary to rebuild a water barrier and to regain other protective functions of the skin. It is interesting

to note that the number of stratified epidermal layers vary in different animal species, for example, mouse skin epidermis is made up with three epidermal layers: basal layer, suprabasal layer, and the stratum corneum. Despite the variation, the strata basale and corneum are always the basic essential components of the stratified epidermis. Thus, a central theme is that the epidermis repeatedly self-renews to generate the stratum corneum for its water barrier function.

In addition to the epidermis, hair follicles also undergo periodic self-renewal. Specifically, it is the lower portion of the hair follicle epithelium that undergo self-renewal. Both the scalp hair follicles and the vellus hair follicles go through growth (anagen), regression (catagen), and resting (telogen) phases of hair cycle [19]. In human, the scalp hairs may stay in anagen for about two to six years, whereas the catagen lasts for about three weeks, followed by a telogen phase of three to four months. The resident hair follicle stem cells are activated at the beginning of each anagen phase, and these are multipotent stem cells that will generate all epithelial cells of the entire lower hair follicle epithelium. The hair follicle stem cells reside in the upper part of the hair follicle, termed the hair follicle bulge [20, 21], a region of the hair follicle epithelium located beneath the sebaceous gland. In mice, additional groups of hair follicle stem cells have been identified at the isthmus (neck) region of the hair follicles. The isthmus is the portion of hair follicle epithelium located above the sebaceous gland, thus a distinct region from the bulge. While the bulge stem cells contribute transiently to re-epithelializing the skin wound upon injury (the preceding paragraph), based on the studies from mouse models, these isthmus-based stem cells may participate in the normal homeostasis of the stratified epidermis [22].

### 1.3.2 Formation of a Water Barrier

The water barrier function of the stratum corneum can be explained by a “bricks-and-mortar” structure arrangement, with mature corneocytes as “bricks” and intercellular lipid matrix as “mortar” [23–26]. Corneocyte bricks are embedded in the lipid-rich matrix mortar (Figure 1.3). The lipid matrix prevents entry of



**Figure 1.3** The “bricks-and-mortar” barrier model of the stratum corneum with corneocytes as “bricks” and intercellular lipids as “mortar” (a). Multilamellar lipid bilayers secreted from the stratum granulosum to the intercellular space of the corneocytes (b). Transepidermal penetration through the stratum corneum occurs via the intercellular route (blue arrow) through lipid mortar or via the transcellular route (red arrow) passing across corneocytes.

water-soluble compounds from the environment. At the same time, this water barrier prevents water loss from the skin and interior of the body.

The “bricks” property of the corneocytes can be attributed to the cornified cell envelop generated at the periphery of the corneocytes. The 10–15 nm thick cornified envelops are composed of filaggrins, involucrin, and a few other proteins, which are cross-linked by transglutaminases and sulfhydryl oxidases [27]. Keratin filaments in the cytoplasm bound to the interior surface of the cornified envelop, forming thick bundles of fibrous structures intracellularly. Since corneocytes are devoid of nuclei, organelles and water, these cornified cells are essentially filled with proteins. External to the cornified envelop, a lipid envelop is attached covalently to the cornified envelop, likely via cross-link to involucrin [27, 28]. Whereas the cornified envelop confers corneocytes a lower permeability, this envelop contributes to a strong and resilient cell. With multiple layers of cornified cells, in addition to a water barrier function, the stratum corneum also protect the skin against abrasions, heat, light, and other external assaults [29].

The “mortar,” or intercellular lipid matrix, are stacks of lipid bilayers that form a multilamellar pattern. The main composition of the intercellular lipids are ceramides, cholesterol, and free fatty acids, at more or less equimolar ratio [27, 30–32]. A small percentage of other lipids are present but phospholipids are absent from this lipid matrix. The lipid matrix is not all the same within the stratum corneum: in the upper zone of stratum corneum, the lipid matrix is less compact, whereas in the basal/intermediate zone, the lipid matrix is more compact, thus serves as the main diffusion barrier.

It was proposed that the multilamellar lipid matrix are generated and packed in lamellar bodies derived from the Golgi apparatus in stratum granulosum [33, 34]. Within the most superior granular cells, as the lipids-containing lamellar bodies reach the plasma membrane, they are fused with the plasma membrane, and their contents are released to the intercellular space, forming the intercellular lamellar lipid bilayers [27, 35–37]. Defects in the formation and maturation of cornified cell envelop or the lipid lamellar bodies will lead to a disrupted water barrier of the stratum corneum [15, 29, 38, 39].

In addition to a “bricks” and “mortar” organization as the basis of a water barrier, corneocytes are connected to each other via specialized desmosomes known as corneodesmosomes [40], which are composed of desmoplakins, desmogleins, desmocollins, plakoglobins, and desmocalmins. The corneodesmosomes provide mechanical and chemical protection for the stratum corneum and contribute to the formation of a water barrier. Breakdowns of corneodesmosomes generate lacunar spaces [41] that disrupt the barrier. Nonetheless, regulations on safeguarding a water barrier is not limited to maintaining an intact stratum corneum. Disruption of cell–cell junctions in other epidermal layers, such as tight junctions in the stratum granulosum, also resulted in a defective water barrier [27].

### 1.3.3 Getting Across the Water Barrier

Strictly speaking, the stratum corneum is semipermeable, not fully impermeable. The hydrophilic and hydrophobic poles of the lipid bilayers allow passage of external substances, albeit slowly. Permeation through the stratum corneum happens

by passive diffusion, either via the intercellular space (intercellular/paracellular) or via the corneocytes (transcellular) (Figure 1.3). These are the transepidermal route of getting through the stratum corneum [1]. The diffusion rate depends on the “solubilities” of the substance. Usually, lipophilic molecules are preferred for passage through the intercellular space, whereas polar or hydrophilic molecules preferred the transcellular route. Therefore, it is possible to administer drug topically through the skin. The permeation via the lipid mortar can be manipulated by careful design of the hydrophobic versus hydrophilic ratio and the type of lipid used [42, 43]. This has become an area of extensive studies while at the same time to further characterize the transepidermal route of external substances [44].

Once the molecule passes through the stratum corneum, the live epidermal cells in the lower epidermal layers have little resistance to diffusion of these external substances. As the molecules or external substances arrive in the dermis, they enter the systemic circulation perhaps via the plexuses underneath the epidermis [45]. On a different note, topical drug administration can also be introduced through the opening of skin appendages. So far, the hair follicle is a reasonable route. In addition, the aqueous pathway (lacunar space) generated by breakdowns of corneodesmosomes has leads to an idea of mechanical delivery by generating pores in epidermis, perhaps transiently, to allow drug delivery into the skin [46].

## References

- 1 Hwa, C., Bauer, E.A., and Cohen, D.E. (2011). Skin biology. *Dermatol. Ther.* 24 (5): 464–470.
- 2 Chuong, C.M., Nickoloff, B.J., Elias, P.M. et al. (2002). What is the ‘true’ function of skin? *Exp. Dermatol.* 11 (2): 159–187.
- 3 Murakami, M., Ohtake, T., Dorschner, R.A. et al. (2002). Cathelicidin anti-microbial peptide expression in sweat, an innate defense system for the skin. *J. Invest. Dermatol.* 119: 1090–1095, 5.
- 4 Butnaru, C.A. and Kanitakis, J. (2002). Structure of normal human skin. *Eur. J. Dermatol.* 12 (6): II–IV.
- 5 Kanitakis, J. (2002). Anatomy, histology and immunohistochemistry of normal human skin. *Eur. J. Dermatol.* 12 (4): 390–399. quiz 400-1.
- 6 Skobe, M. and Detmar, M. (2000). Structure, function, and molecular control of the skin lymphatic system. *J. Investig. Dermatol. Symp. Proc.* 5 (1): 14–19.
- 7 Oaklander, A.L. and Siegel, S.M. (2005). Cutaneous innervation: form and function. *J. Am. Acad. Dermatol.* 53 (6): 1027–1037.
- 8 Chopra, K., Calva, D., Sosin, M. et al. (2015). A comprehensive examination of topographic thickness of skin in the human face. *Aesthet. Surg. J.* 35 (8): 1007–1013.
- 9 Laurent, A., Mistretta, F., Bottiglioli, D. et al. (2007). Echographic measurement of skin thickness in adults by high frequency ultrasound to assess the appropriate microneedle length for intradermal delivery of vaccines. *Vaccine* 25 (34): 6423–6430.

- 10 Sandby-Moller, J., Poulsen, T., and Wulf, H.C. (2003). Epidermal thickness at different body sites: relationship to age, gender, pigmentation, blood content, skin type and smoking habits. *Acta Derm. Venereol.* 83 (6): 410–413.
- 11 Tagami, H. (2008). Location-related differences in structure and function of the stratum corneum with special emphasis on those of the facial skin. *Int. J. Cosmet. Sci.* 30 (6): 413–434.
- 12 Ya-Xian, Z., Suetake, T., and Tagami, H. (1999). Number of cell layers of the stratum corneum in normal skin – relationship to the anatomical location on the body, age, sex and physical parameters. *Arch. Dermatol. Res.* 291 (10): 555–559.
- 13 Harper, R.A. and Grove, G. (1979). Human skin fibroblasts derived from papillary and reticular dermis: differences in growth potential in vitro. *Science* 204 (4392): 526–527.
- 14 Woodley, D.T. (2017). Distinct fibroblasts in the papillary and reticular dermis: implications for wound healing. *Dermatol. Clin.* 35 (1): 95–100.
- 15 Jensen, J.M. and Proksch, E. (2009). The skin's barrier. *G. Ital. Dermatol. Venereol.* 144 (6): 689–700.
- 16 Alonso, L. and Fuchs, E. (2003). Stem cells of the skin epithelium. *Proc. Natl. Acad. Sci. U. S. A.* 100 (Suppl. 1): 11830–11835.
- 17 Fuchs, E. (2016). Chapter nineteen – epithelial skin biology: three decades of developmental biology, a hundred questions answered and a thousand new ones to address. *Curr. Top. Dev. Biol.* 118: 357–374.
- 18 Ito, M., Liu, Y., Yang, Z. et al. (2005). Stem cells in the hair follicle bulge contribute to wound repair but not to homeostasis of the epidermis. *Nat. Med.* 11 (12): 1351–1354.
- 19 Alonso, L. and Fuchs, E. (2006). The hair cycle. *J. Cell Sci.* 119 (Pt 3): 391–393.
- 20 Cotsarelis, G. (2006). Epithelial stem cells: a folliculocentric view. *J. Invest. Dermatol.* 126 (7): 1459–1468.
- 21 Tiede, S., Kloepper, J.E., Bodò, E. et al. (2007). Hair follicle stem cells: walking the maze. *Eur. J. Cell Biol.* 86 (7): 355–376.
- 22 Plikus, M.V., Gay, D.L., Treffeisen, E. et al. (2012). Epithelial stem cells and implications for wound repair. *Semin Cell Dev. Biol.* 23 (9): 946–953.
- 23 Nemes, Z. and Steinert, P.M. (1999). Bricks and mortar of the epidermal barrier. *Exp. Mol. Med.* 31 (1): 5–19.
- 24 Venus, M., Waterman, J., and McNab, I. (2010). Basic physiology of the skin. *Surgery (Oxford)* 28 (10): 469–472.
- 25 Baroni, A., Buommino, E., De Gregorio, V. et al. (2012). Structure and function of the epidermis related to barrier properties. *Clin. Dermatol.* 30 (3): 257–262.
- 26 Harding, C.R. (2004). The stratum corneum: structure and function in health and disease. *Dermatol. Ther.* 17 (Suppl 1): 6–15.
- 27 Madison, K.C. (2003). Barrier function of the skin: “la raison d’être” of the epidermis. *J. Invest. Dermatol.* 121 (2): 231–241.
- 28 Swartzendruber, D.C., Wertz, P.W., Madison, K.C. et al. (1987). Evidence that the corneocyte has a chemically bound lipid envelope. *J. Invest. Dermatol.* 88 (6): 709–713.

- 29 Elias, P.M. and Choi, E.H. (2005). Interactions among stratum corneum defensive functions. *Exp. Dermatol.* 14 (10): 719–726.
- 30 Lampe, M.A., Burlingame, A.L., Whitney, J. et al. (1983). Human stratum corneum lipids: characterization and regional variations. *J. Lipid Res.* 24 (2): 120–130.
- 31 Marekov, L.N. and Steinert, P.M. (1998). Ceramides are bound to structural proteins of the human foreskin epidermal cornified cell envelope. *J. Biol. Chem.* 273 (28): 17763–17770.
- 32 Wertz, P.W. (2013). Current understanding of skin biology pertinent to skin penetration: skin biochemistry. *Skin Pharmacol. Physiol.* 26 (4–6): 217–226.
- 33 Proksch, E., Brandner, J.M., and Jensen, J.M. (2008). The skin: an indispensable barrier. *Exp. Dermatol.* 17 (12): 1063–1072.
- 34 Rassner, U., Feingold, K.R., Crumrine, D.A., and Elias, P.M. (1999). Coordinate assembly of lipids and enzyme proteins into epidermal lamellar bodies. *Tissue Cell* 31 (5): 489–498.
- 35 Menon, G.K., Cleary, G.W., and Lane, M.E. (2012). The structure and function of the stratum corneum. *Int. J. Pharm.* 435 (1): 3–9.
- 36 Ishida-Yamamoto, A., Igawa, S., and Kishibe, M. (2011). Order and disorder in corneocyte adhesion. *J. Dermatol.* 38 (7): 645–654.
- 37 Ishida-Yamamoto, A., Igawa, S., and Kishibe, M. (2018). Molecular basis of the skin barrier structures revealed by electron microscopy. *Exp. Dermatol.* 27 (8): 841–846.
- 38 Nickoloff, B.J. and Naidu, Y. (1994). Perturbation of epidermal barrier function correlates with initiation of cytokine cascade in human skin. *J. Am. Acad. Dermatol.* 30 (4): 535–546.
- 39 Wood, L.C., Elias, P.M., Calhoun, C. et al. (1996). Barrier disruption stimulates interleukin-1 alpha expression and release from a pre-formed pool in murine epidermis. *J. Invest. Dermatol.* 106 (3): 397–403.
- 40 Elias, P.M. (2004). The epidermal permeability barrier: from the early days at Harvard to emerging concepts. *J. Invest. Dermatol.* 122 (2): xxxvi–xxxix.
- 41 Menon, G.K. and Elias, P.M. (1997). Morphologic basis for a pore-pathway in mammalian stratum corneum. *Skin Pharmacol.* 10 (5–6): 235–246.
- 42 Das, C., Noro, M.G., and Olmsted, P.D. (2009). Simulation studies of stratum corneum lipid mixtures. *Biophys. J.* 97 (7): 1941–1951.
- 43 Prausnitz, M.R., Mitragotri, S., and Langer, R. (2004). Current status and future potential of transdermal drug delivery. *Nat. Rev. Drug Discov.* 3 (2): 115–124.
- 44 Volz, P., Boreham, A., Wolf, A. et al. (2015). Application of single molecule fluorescence microscopy to characterize the penetration of a large amphiphilic molecule in the stratum corneum of human skin. *Int. J. Mol. Sci.* 16 (4): 6960–6977.
- 45 Naik, A., Kalia, Y.N., and Guy, R.H. (2000). Transdermal drug delivery: overcoming the skin's barrier function. *Pharm. Sci. Technol. Today* 3 (9): 318–326.
- 46 Honari, G. and Malbach, H. (2014). Chapter 1 – Skin structure and function. In: *Applied Dermatoxicology*, 1–10. Elsevier <https://www.sciencedirect.com/science/article/pii/B9780124201309000013>.