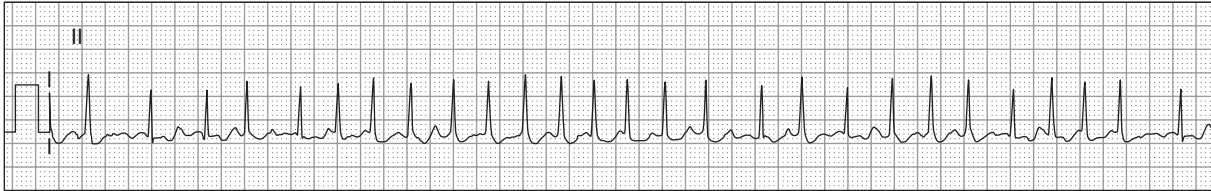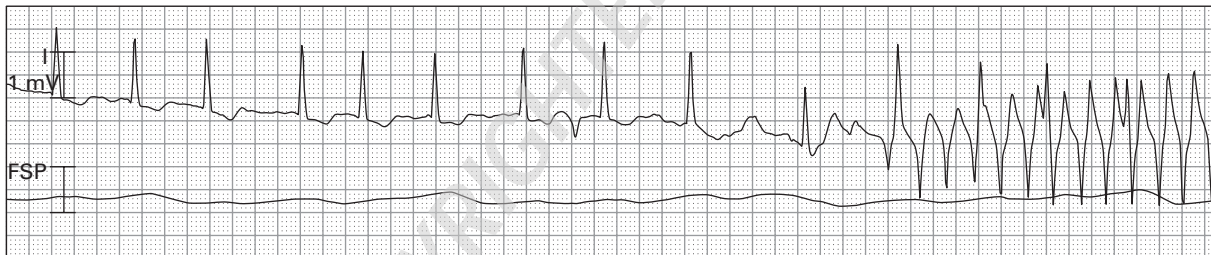

Case histories

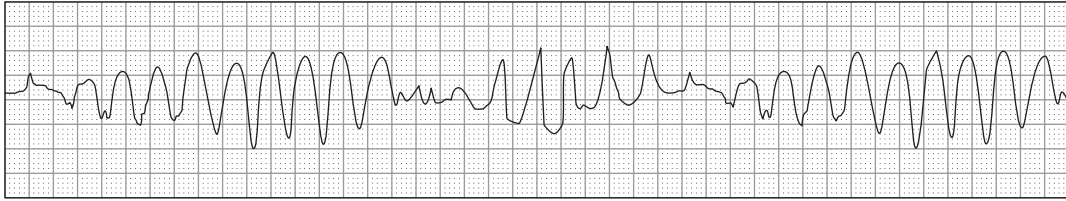


1. 63-year-old woman with palpitations, weakness, and dyspnea

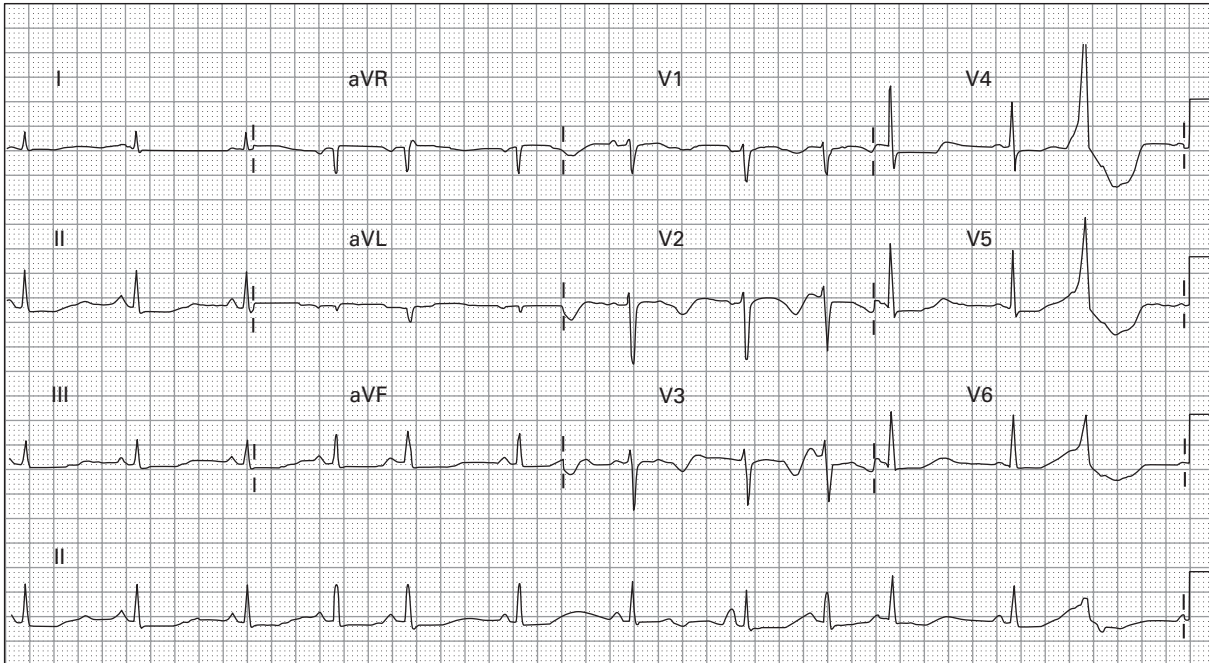


2. 71-year-old febrile man with pneumonia

a)

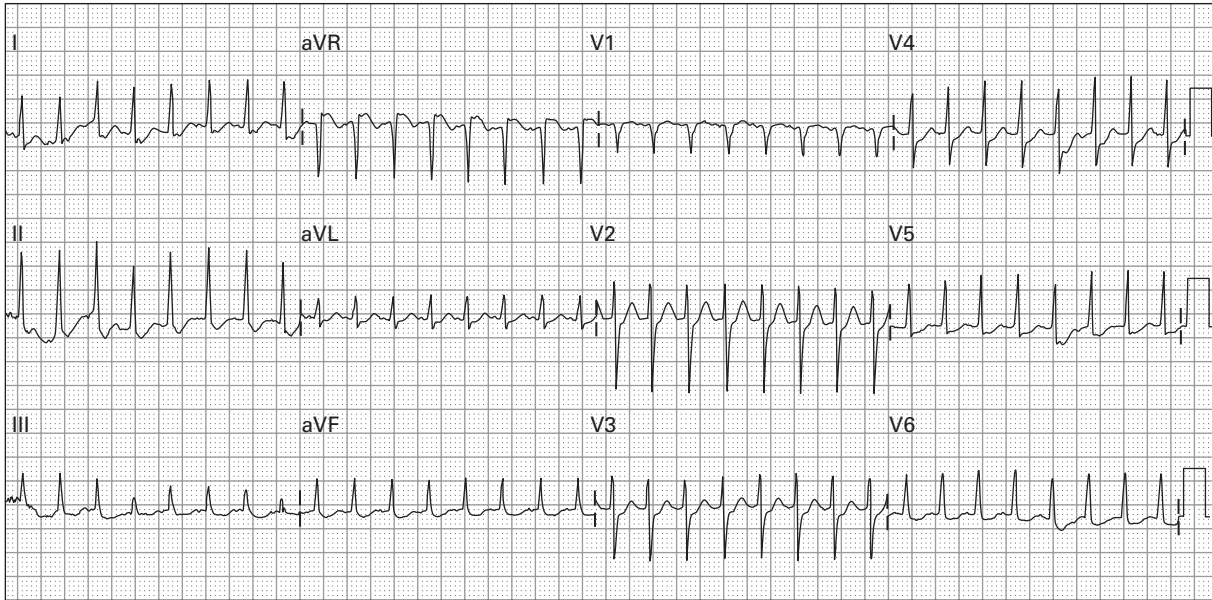


b)

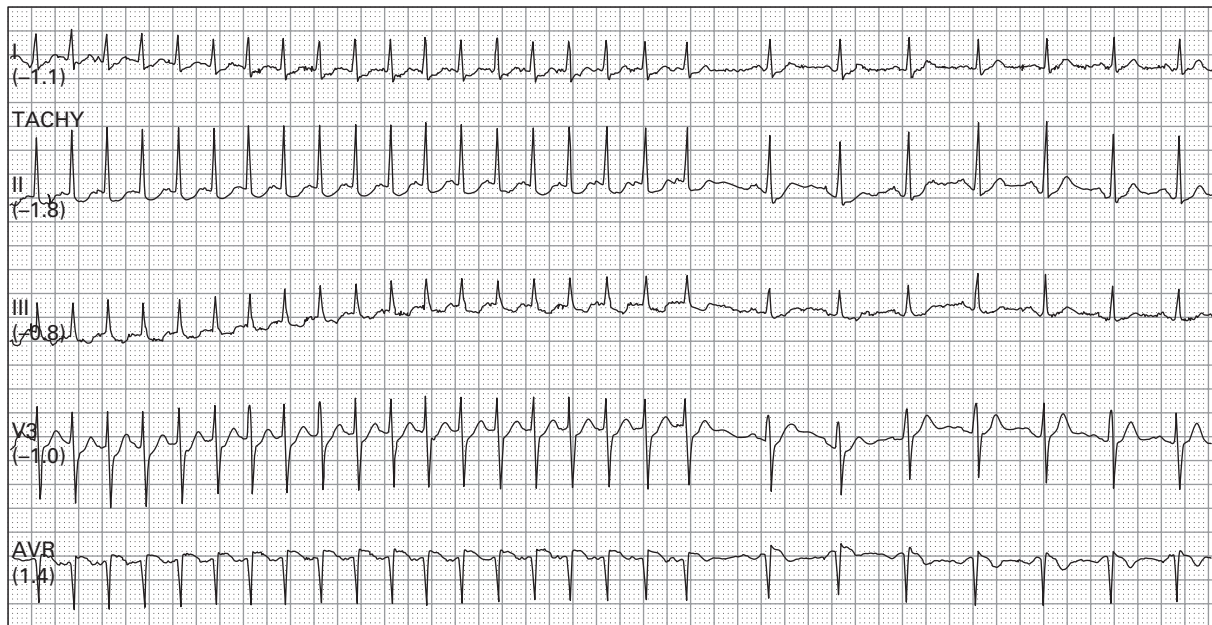


3. 54-year-old dehydrated woman with gastroenteritis and recurrent syncope: a) at the onset of "syncope" and b) after resolution of syncope, without medical intervention

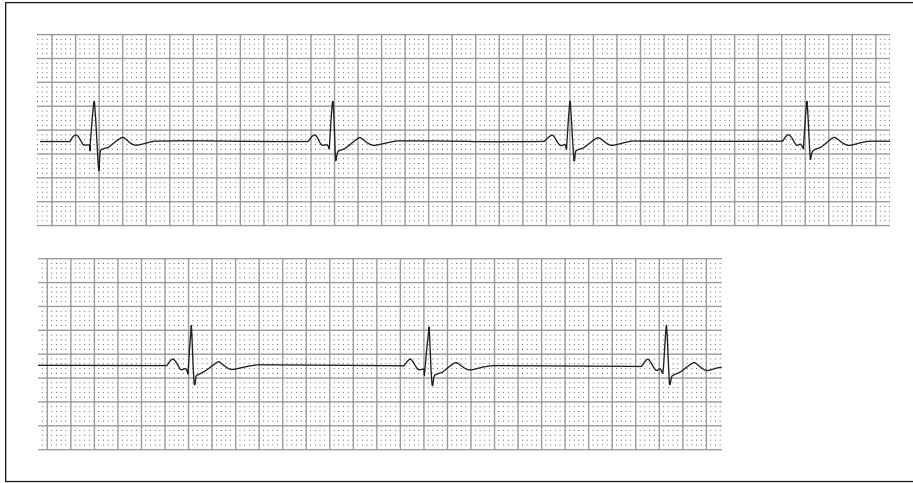
a)



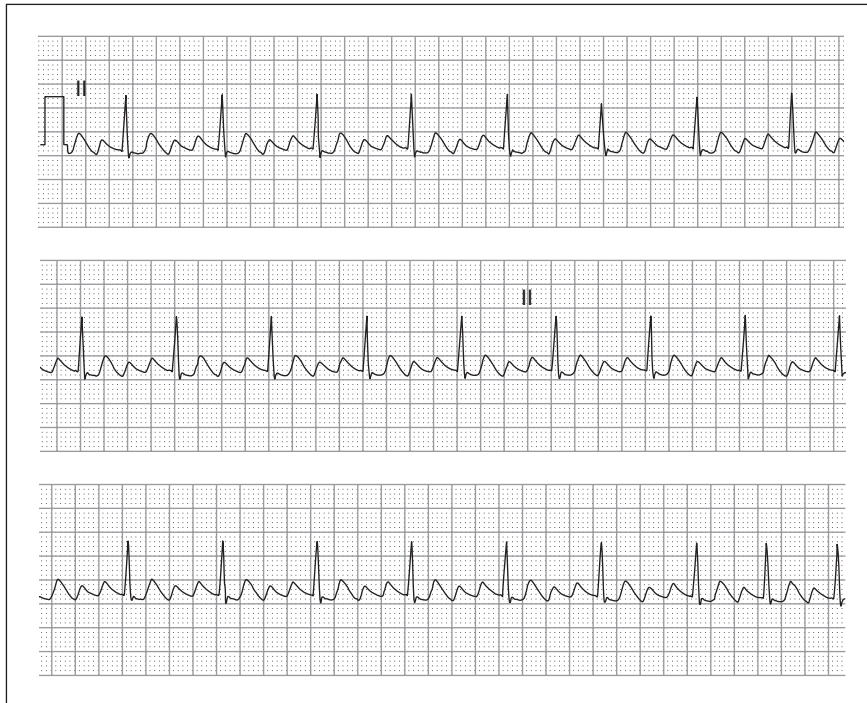
b)



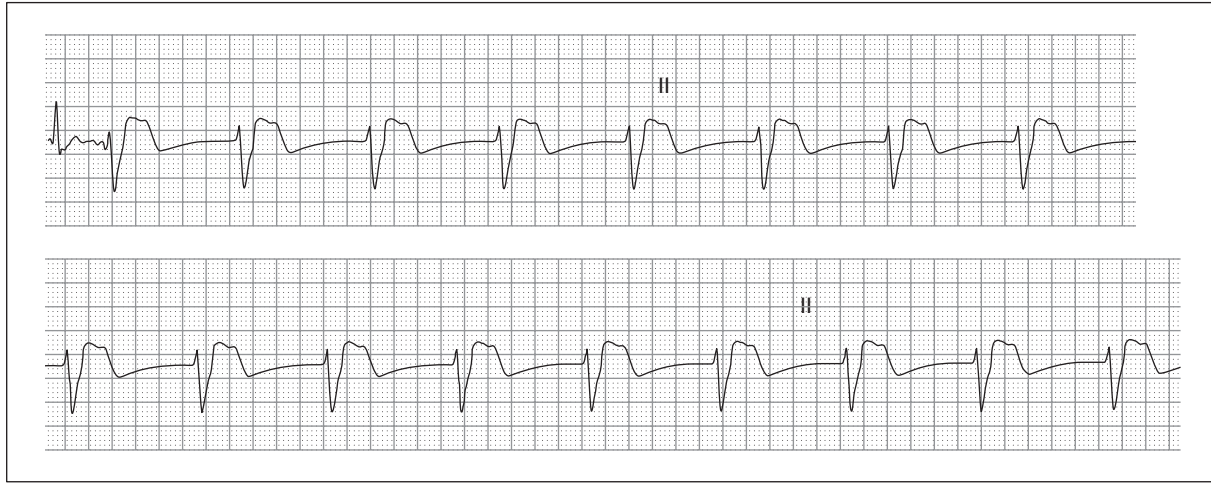
4. a) 18-year-old woman with palpitations, dizziness, and hypotension, b) during treatment



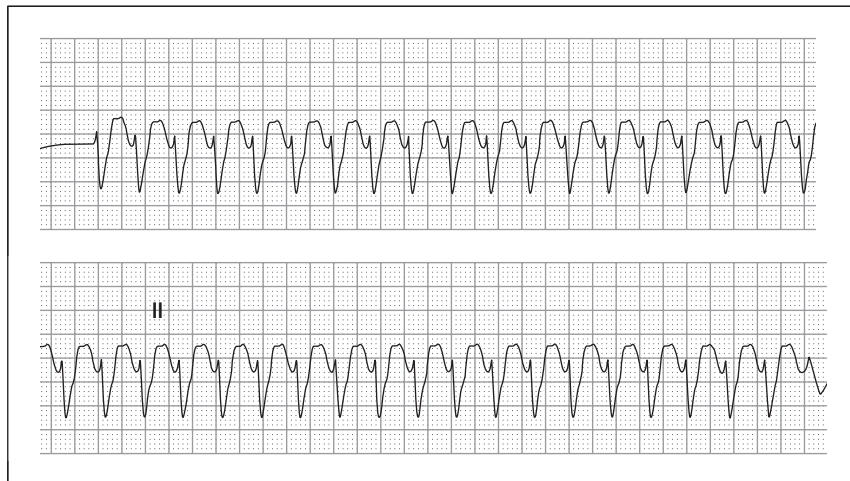
5. 68-year-old man with hypertension, managed with multiple cardiac medications, presenting with profound weakness



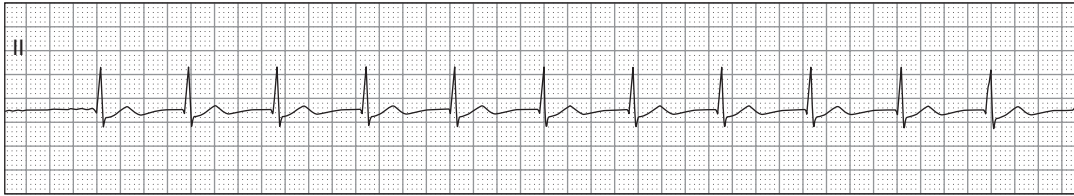
6. 57-year-old woman with palpitations and exercise intolerance



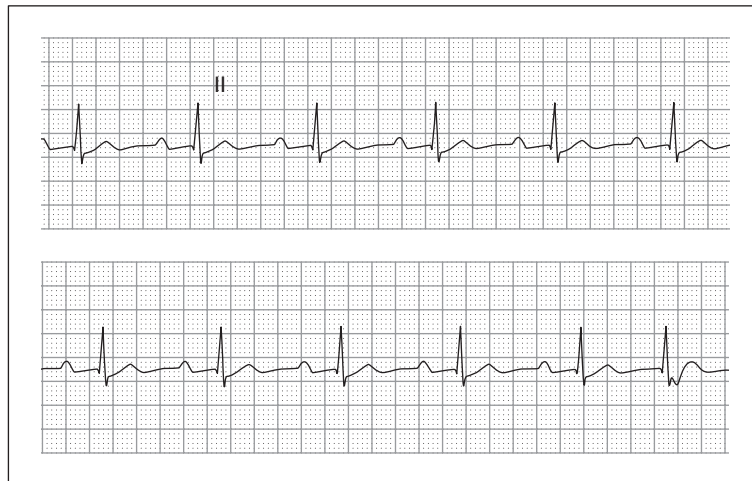
7. 42-year-old man, 30 minutes after receiving fibrinolytics for an acute myocardial infarction (MI)



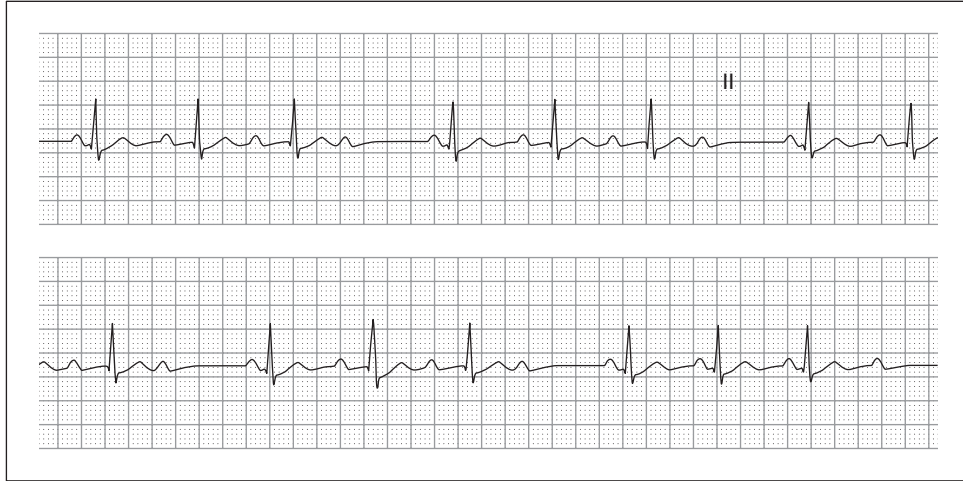
8. 53-year-old man, with a history of MI, presenting with weakness, palpitations, hypotension, and acute pulmonary edema



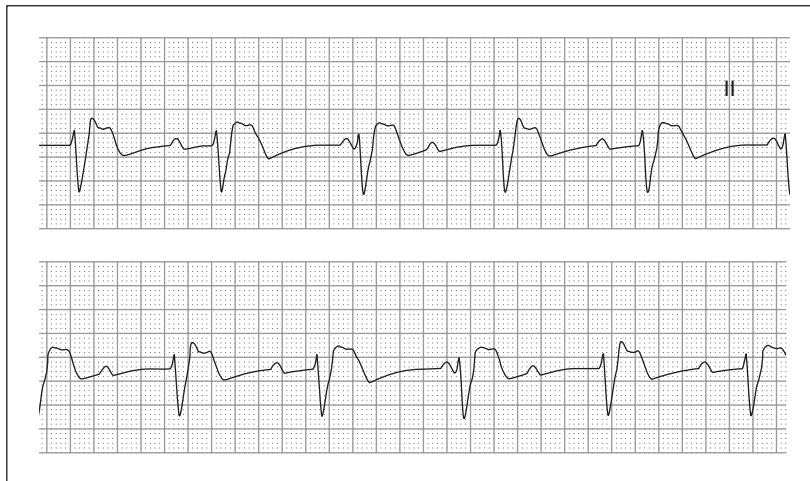9. 79-year-old woman, with hypertension and chronic congestive heart failure, complaining of weakness and dyspnea



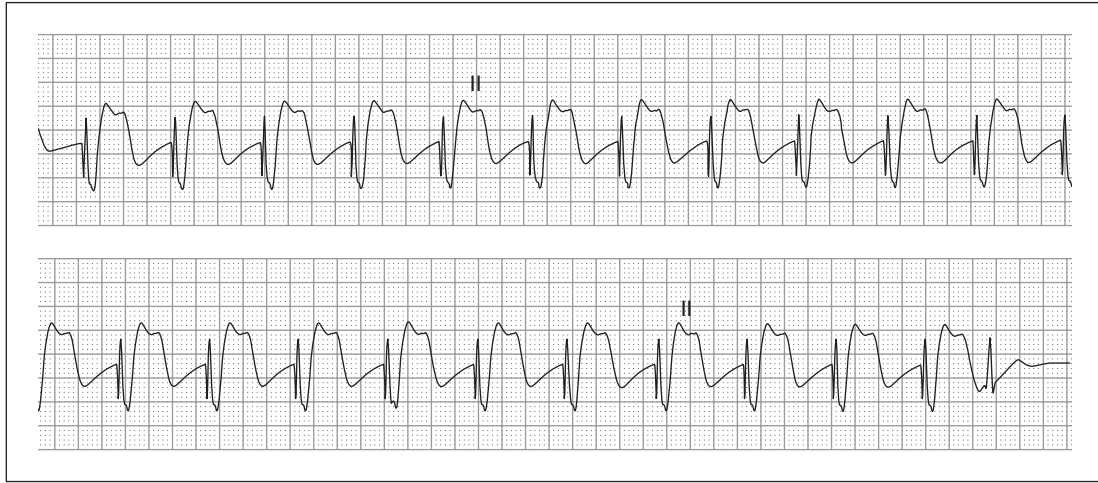10. 29-year-old man presenting with an ankle fracture; he has no cardiovascular symptoms and is a long-distance runner



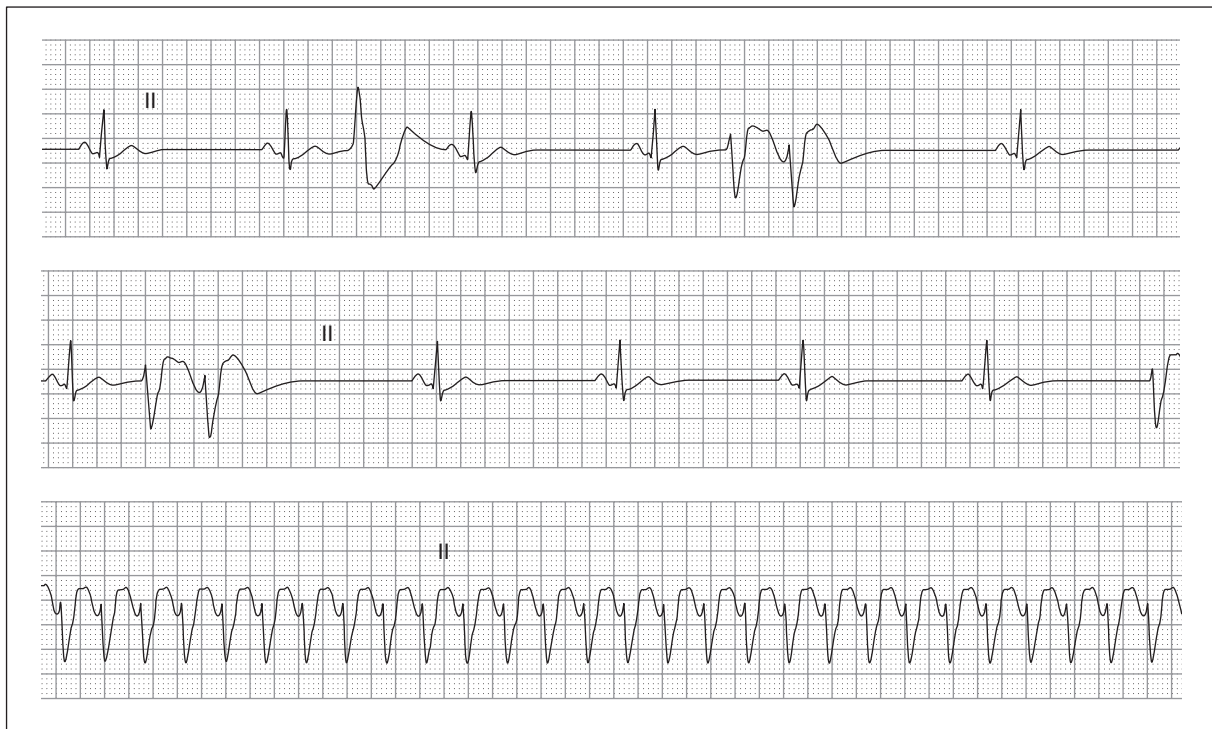
11. 71-year-old woman with syncope



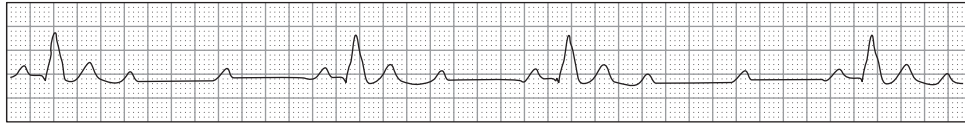
12. 79-year-old man with progressive weakness



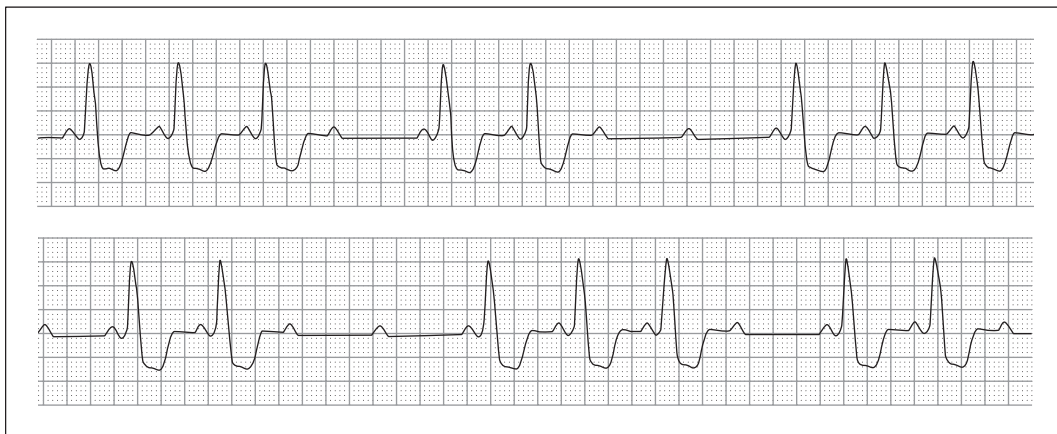13. 59-year-old woman who is being transcutaneously paced



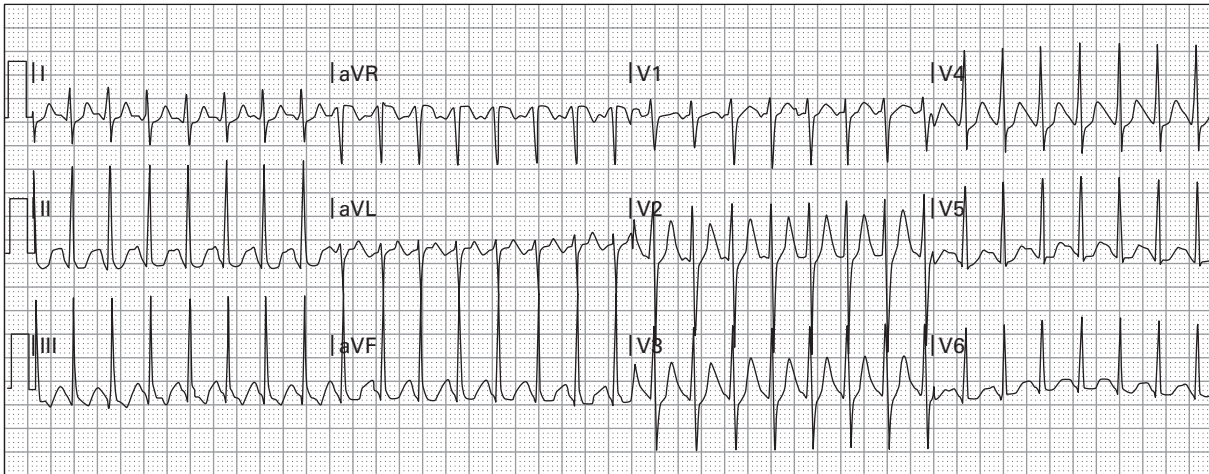
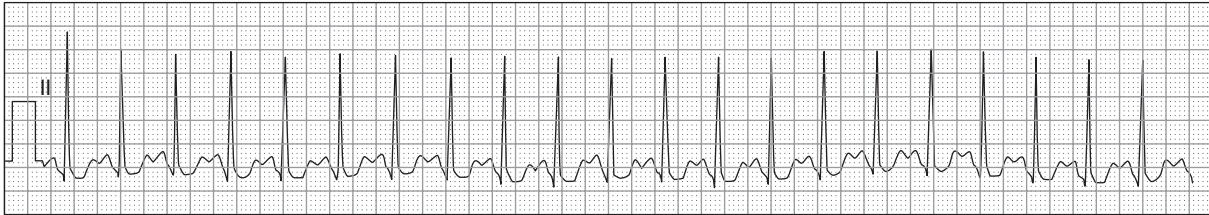
14. 68-year-old woman with sudden loss of consciousness; note the continuous rhythm strip



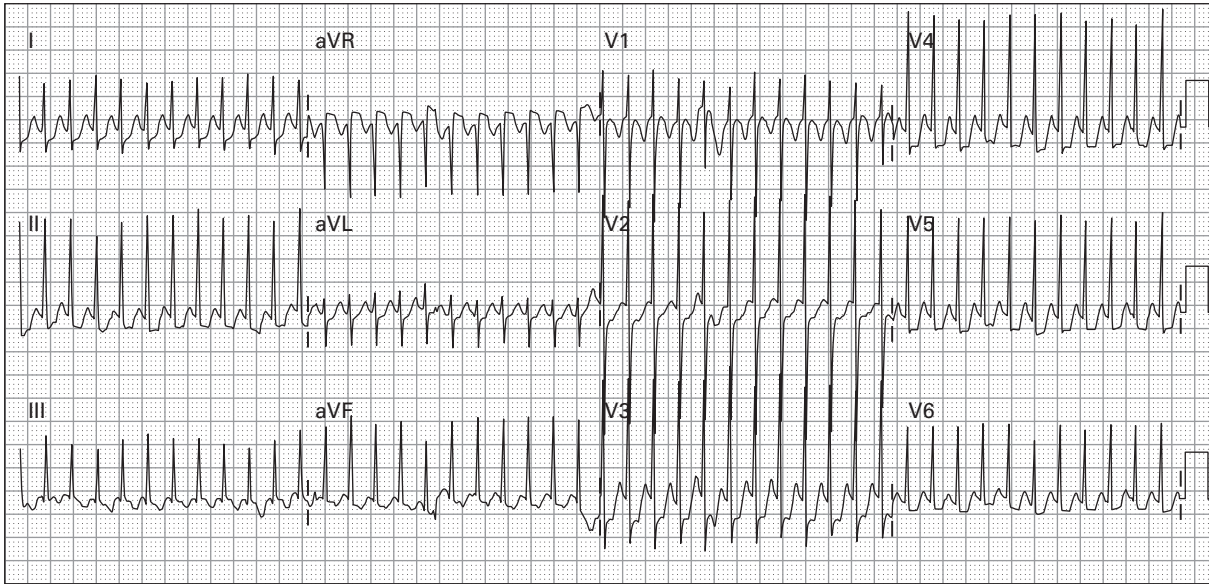
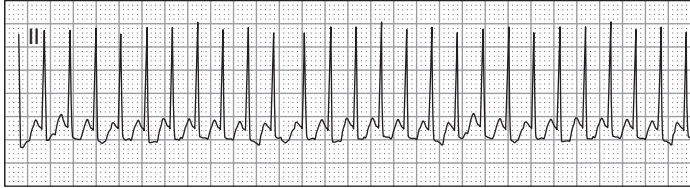
15. 66-year-old man, with a history of sick sinus syndrome and hypertension, who notes extreme dizziness



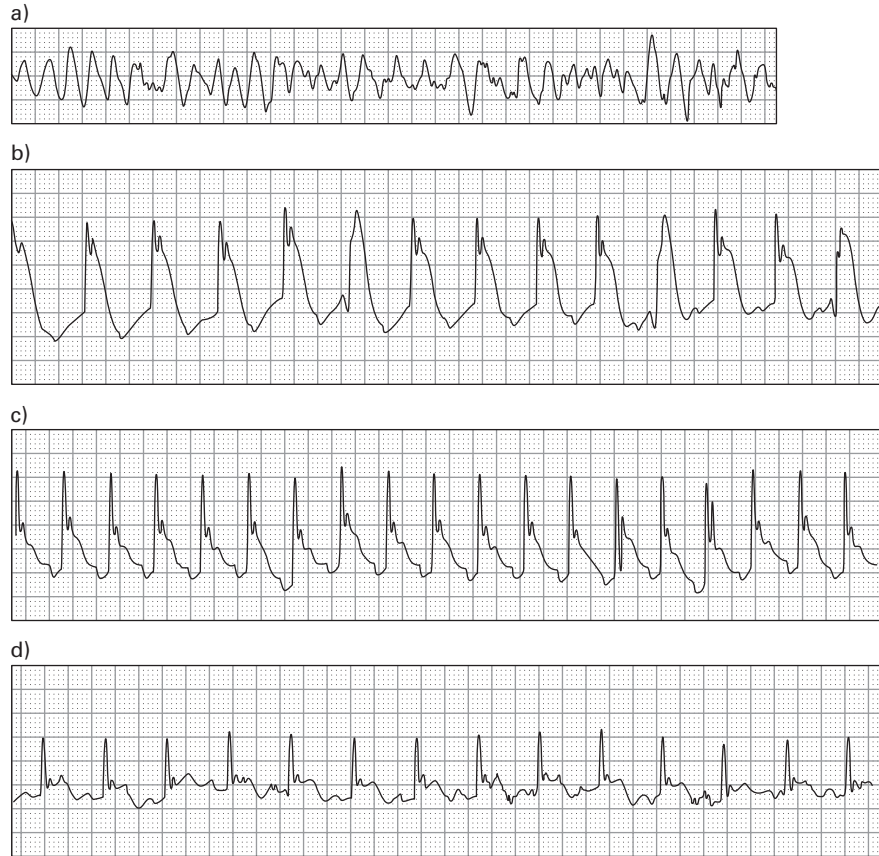16. 56-year-old woman with acute MI, which occurred one day earlier



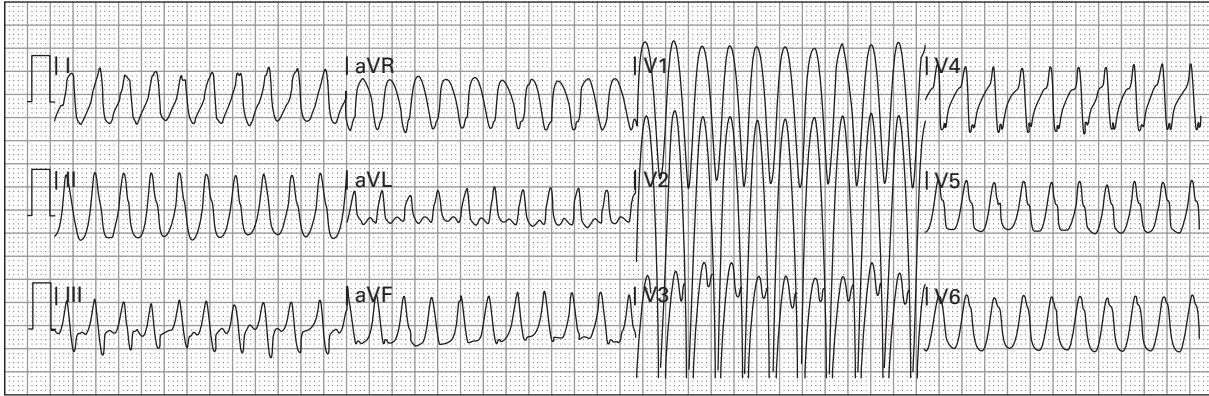
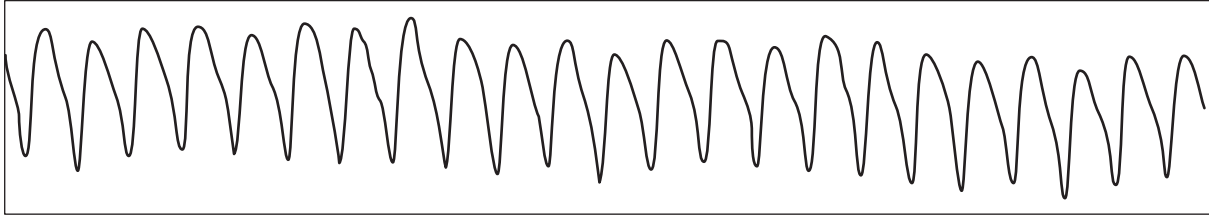
17. 26-year-old woman with extreme anxiety after cocaine use (nasal)



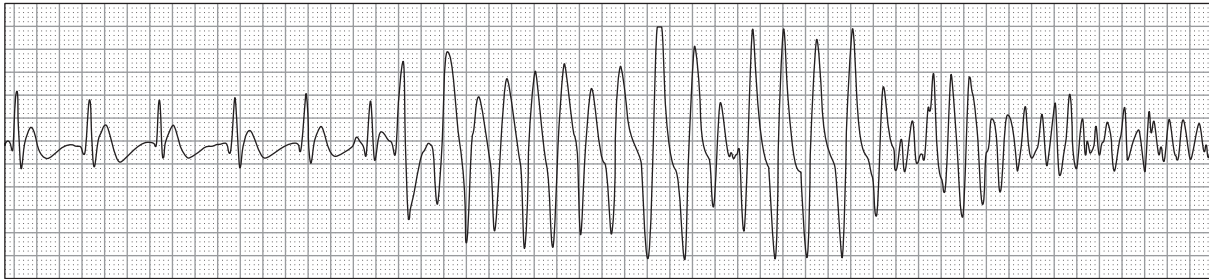
18. 18-month-old child with fussiness and poor feeding



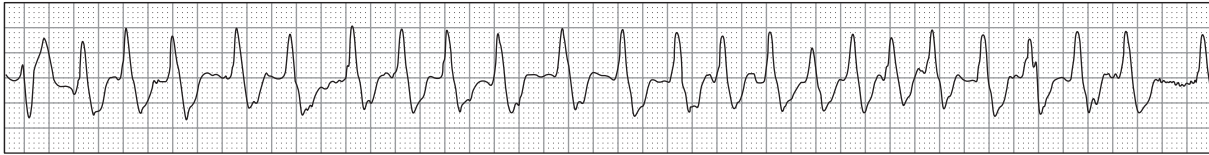
19. 54-year-old man with chest pain: a) sudden development of cardiac arrest, b) after defibrillation, return of spontaneous circulation with blood pressure 115/72 mmHg, c) continued improvement with blood pressure 108/69 mmHg, and d) alert with chest pain and blood pressure 109/76 mmHg



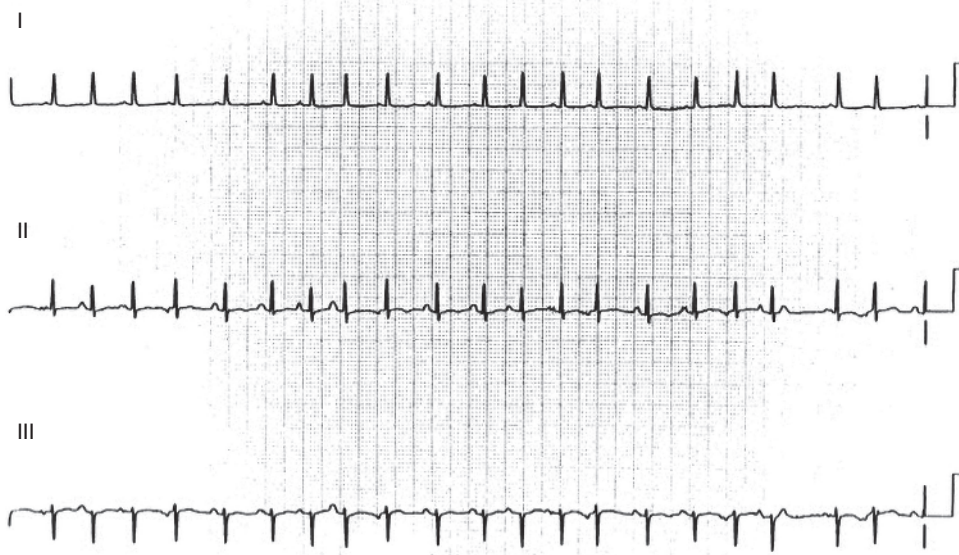
20. 60-year-old man, with a history of congestive heart failure, presenting with dyspnea, profound weakness, and hypotension



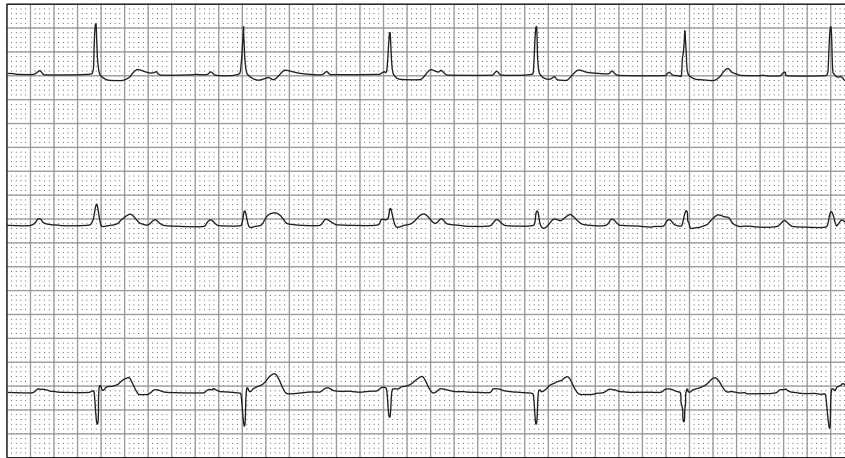
21. 65-year-old woman presenting with chest pain suspected of acute coronary syndrome and sudden loss of consciousness



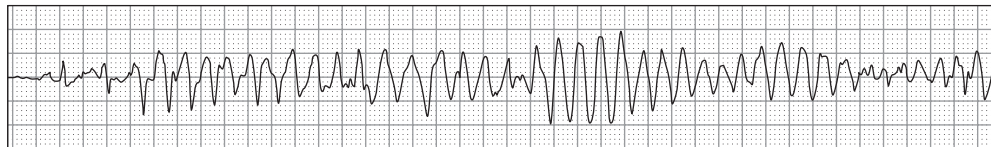
22. 67-year-old woman with the sensation of a rapid heart beat



23. 65-year-old man with chronic obstructive pulmonary disease and acute dyspnea



24. 75-year-old woman with altered mental status



25. 16-year-old boy presents after a syncopal episode, now with recurrent sudden loss of consciousness